

## Low Grade Abdominal Leiomyosarcoma with Liver Metastasis: A Second Cancer Twenty Years after Treatment for Nasopharyngeal Cancer

Yosra Yahyaoui<sup>1</sup>, Achref Ghorbel<sup>1</sup>, Lamia Charfi<sup>2</sup>, Ahmed Gammoudi<sup>1</sup>, Yosr Zenzri<sup>1</sup>, Azza Gabsi<sup>1</sup> and Amel Mezlini<sup>1</sup>.  
<sup>1</sup> Medical Oncology Department, Faculty of Medicine of Tunis, Salah Azaiez Institute, El Manar University, Tunis, Tunisia.  
<sup>2</sup> Pathology Department, Faculty of Medicine of Tunis, Salah Azaiez Institute, El Manar University, Tunis, Tunisia.

\*Corresponding Author:

Yahyaoui Yosra, Medical Oncology Department, Faculty of Medicine of Tunis, Salah Azaiez Institute, El Manar University, Tunis, Tunisia.

### Abstract:

**Background:** leiomyosarcoma is one of the most frequent soft tissues and abdominal-pelvic sarcomas however intra-abdominal leiomyosarcoma with liver metastasis remain a very rare disease.

**Case presentation:** A 61 year-old man presented in February 2019 a recent history of abdominal pain and weight loss. Imagery showed a 5 cm abdominal mass with multiples liver lesions. Biopsy of the liver lesions concluded to a metastases of a low grade leiomyosarcoma. Surgical resection was deemed not possible due to anatomical restrictions and the patient received 6 cycles of systemic mono-chemotherapy with epirubicin. A CT scan performed after the chemotherapy showed a stable disease using RECIST criteria.

**Conclusions:** In case of an unresectable liver metastasis palliative chemotherapy can be offered although it is widely recognized that leiomyosarcoma show moderate sensitivity to chemotherapy.

**Keywords:** leiomyosarcoma; soft tissue sarcoma; anthracyclines; case report

### Introduction:

Leiomyosarcoma (LMS) is a type of malignant soft tissue sarcoma of smooth muscle that may occur anywhere in the body. Abdominal LMS is highly aggressive with an overall 5 year survival rate ranging between 20 and 30 % [1].

Wide resection is the standard treatment for LMS. Hepatic metastases from soft tissue sarcomas are rare and the treatment has not been standardized. Anthracycline monotherapy and combination chemotherapy containing doxorubicin are options for treating metastatic soft tissue sarcoma [2]. Here we report a case of a metastatic LMS that developed in a 61-year-old man 20 years after he was treated for a nasopharyngeal carcinoma

### Case presentation:

A 61 year-old man, non-smoker, treated in 1999 with chemotherapy and radiotherapy for an undifferentiated nasopharyngeal cancer classified at the time T3N3M0 presented in February 2019 a recent history of abdominal pain and weight loss. He underwent a full body scan that showed a 5 cm abdominal mass located in front of the vascular axis of the

left iliac region with multiple liver metastases. Biopsy of the left iliac mass concluded to smooth muscle tumor without clear sign of malignancy as some moderate cytonuclear atypia was seen without necrosis or mitosis (Figure1). Immunohistochemistry was positive for desmine and caldesmone but negative for CD34 and PS100. A fine needle biopsy of a hepatic lesion showed a hepatic parenchyma widely invaded by a mesenchymal proliferation of variable density depending on the territory. The proliferation was made of fusiform cells with an oval nucleus of slightly unequal size with finely granular chromatin, those cells were arranged in crisscrossed beams. Mitosis were rare (1 mitosis/ 10 high power fields (HPF) and no necrosis was seen. Tumor cells stained positive in Immunohistochemistry for caldesmone (Figure2) and negative for CD34, Ckit, Dog1, HMB45 and CK.

The diagnosis of liver metastasis of a low grade abdominal leiomyosarcoma was made. After multidisciplinary assessment, surgical resection was not deemed possible due to anatomical restrictions and the patient received a systemic mono-chemotherapy with epirubicin (75mg/m<sup>2</sup>). The CT scan performed after six cycles of chemotherapy showed a stable disease using RECIST criteria. At the time of finalization of this report, and 8 months post-treatment, the patient was still alive.

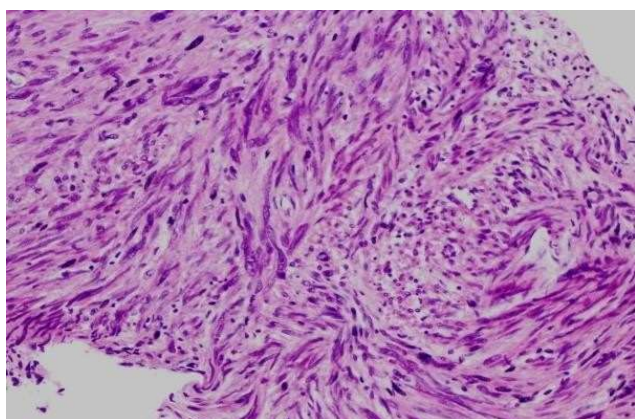


Figure 1: Micrographs of the liver metastasis

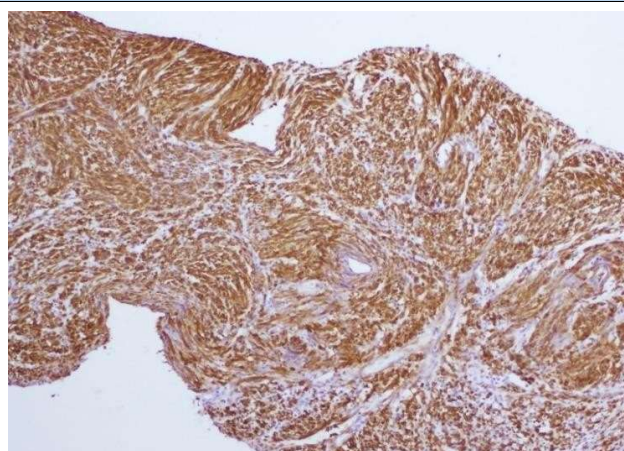


Figure 2: Immunohistochemistry for caldesmon

### Discussion:

Leiomyosarcoma is one of the most frequent soft tissues and abdominal-pelvic sarcomas [3], however intra-abdominal LMS with liver metastasis remain a very rare disease. Surgical resection should be offered for all patient as long term survival can be achieved after an R0 resection [4].

In case of an unresectable liver metastasis palliative chemotherapy can be offered although it is widely recognized that LMS show moderate sensitivity to chemotherapy [5].

Single-agent anthracyclines and specially doxorubicin is a standard systemic treatment of soft tissue sarcomas, and subsequently for LMS although it showed a lower response rate compared with other sarcoma types [6]. Epirubicin can also be used as it is less cardiotoxic and provides outcomes that are comparable with doxorubicin [3].

Causes and predisposing factors of LMS remains unclear although Epstein-Barr virus (EBV) infection has been associated with LMS in the setting of severe immunosuppression such as the association of EBV with LMS in young people with AIDS shown by McClain et al [7]. Immunodeficient individuals are also prone to develop Epstein-Barr Virus-Associated Smooth Muscle Tumor (EBV-SMT) which represent a heterogeneous group of disorders with a broad pathological spectrum ranging from leiomyoma-like to leiomyosarcoma-like tumors [8]. In such cases, the detection of EBV in the tumor cells remains the mainstay for distinguishing them from conventional leiomyosarcoma [9].

In our case, although the biopsy of the left iliac mass concluded to smooth muscle tumor without clear sign of malignancy we still think that this mass is probably the primary site of the LMS as it is possible that the small fragment that was taken out may not be relevant to all the tumor.

Our patient had a history of an undifferentiated nasopharyngeal cancer which is also EBV related, however we were not able to do the detection of EBV in tumor cells in order to exclude an EBV-SMT, although the fusiform cells proliferation remains in favor of conventional LMS. This medical history underlines the importance of this case as it is interesting by the rarity of a second cancer after treatment for nasopharyngeal cancer in a Tunisian patient (Tunisia being an area of intermediate incidence), outside the field of radiotherapy, usual area of second malignancies. Also the non-response to chemotherapy and the unusual clinical presentation made us question the initial diagnosis of abdominal sarcoma and to discuss a gastrointestinal stromal tumor (GIST). A paper published in 2019 by Guohua Yu et al showed that GIST outside the gastrointestinal tract or with CD117-negative expression may be misdiagnosed as smooth muscle tumor because of the positive expression of H-caldesmon. In this paper H-caldesmon was positive in five cases outside the gastrointestinal tract and in two other cases that were CD117 negative, and all of those cases were diagnosed as GIST and confirmed by genetic sequencing.[10]

### Conclusion:

Surgical resection remains the first-line treatment of metastatic low grade abdominal LMS. However, anthracycline chemotherapy may be indicated in patients whose abdominal LMS is unresectable. Due to the disease's poor prognosis, ongoing evaluation of current therapy and development of new treatment strategies are required.

### References:

1. Hashimoto H, Tsuneyoshi M, Enjoji M. Malignant smooth muscle tumors of the retroperitoneum and mesentery: a clinicopathologic analysis of 44 cases. *J Surg Oncol* 1985;28:177–86. Doi: 10.1002/jso.2930280307.
2. Marshall S, Nakano K, Sugiura Y, Taira S, Ono M, Tomomatsu J, et al. Outcome for Advanced or Metastatic Soft Tissue Sarcoma of Nonextremities Treated with Doxorubicin-Based Chemotherapy: A Retrospective Study from a Single Cancer Institution. *Sarcoma* 2018;2018:1–7. Doi:10.1155/2018/8926598.
3. Serrano C, George S. Leiomyosarcoma. *Hematol Oncol Clin North Am* 2013;27:957–74. DOI: 10.1016/j.hoc.2013.07.002
4. Kim YW, Lee JH, Kim JE, Kang J. Surgical resection of liver metastasis of leiomyosarcoma. *Korean J Clin Oncol* 2017;13:143–6. DOI: 10.14216/kjco.17022.
5. Grimer R, Judson I, Peake D, Seddon B. Guidelines for the Management of Soft Tissue Sarcomas. *Sarcoma* 2010;2010:1–15. Doi: 10.1155/2010/506182
6. Karavasilis V, Seddon BM, Ashley S, Al-Muderis O, Fisher C, et al. Significant clinical benefit of first-line palliative chemotherapy in advanced soft-tissue sarcoma: Retrospective analysis and identification of prognostic factors in 488 patients. *Cancer* 2008;112:1585–91. Doi: 10.1002/encr.23332
7. McClain KL, Leach CT, Jenson HB, Joshi VV, Pollock BH, et al. Association of Epstein-Barr Virus with Leiomyosarcomas in Young People with AIDS. *N Engl J Med* 1995;332:12–8. Doi : 10.1056/NEJM199501053320103
8. Magg T, Schober T, Walz C, Ley-Zaporozhan J, Facchetti F, Klein C, et al. Epstein-Barr Virus+ Smooth Muscle Tumors as Manifestation of Primary Immunodeficiency Disorders. *Front Immunol* 2018;9. Doi: 10.3389/fimmu.2018.00368

9. Dekate J, Chetty R. Epstein-Barr Virus–Associated Smooth Muscle Tumor. *Arch Pathol Lab Med* 2016;140:718–22. Doi: 10.5858/arpa.2015-0120-RS
10. Yu G, Xu J, Jiang L, Cai L, Zohar Y, et al. Expression and clinical significance of H-caldesmon in gastrointestinal stromal tumor: is it a specific marker for myogenic differentiation? *Int J Clin Exp Pathol* 2019;12:2566–71.