

# GEL EXTRACT OF PUNTI LASSE BODY (*Musa acuminata* var. *punti lasse* AAA) ON THE INCREASE OF COLLAGEN DENSITY IN THE HEALING PROCESS OF MURDERED MENCITES (*Musculus*)

Imelda Tandirerung<sup>1</sup>, Prihantono<sup>2\*</sup>, Risfah Yulianti<sup>3</sup>,  
Elizabet Catherine Jusuf<sup>4</sup>, Aryadi Arsyad<sup>5</sup> and Mardiana Ahmad<sup>6</sup>

<sup>1</sup> Master, Midwifery Study Programme, Postgraduate Faculty, Hasanuddin University.

<sup>2,4,5,6</sup> Midwifery Study Programme, Postgraduate Faculty, Hasanuddin University.

<sup>3</sup> Department of Pharmacy, Faculty of Pharmacy, Hasanuddin University.

\*Corresponding Author Email: [prihantono@pasca.unhas.ac.id](mailto:prihantono@pasca.unhas.ac.id)

DOI: [10.5281/zenodo.12262124](https://doi.org/10.5281/zenodo.12262124)

## Abstract

**Background:** Wounds that are not treated promptly can lead to serious and life-threatening infections. Potential traditional wound healing is the use of banana stem sap (*Musa acuminata* var. *punti lasse* AAA), which is rich in phytochemicals to accelerate tissue regeneration and increase collagen density. **Objective:** To analyse the effectiveness of banana stem extract (*Musa acuminata* var. *punti lasse* AAA) on increasing collagen density in the wound healing process of female mice (*Mus musculus*). **Methods:** A true experimental research design with post-test only control group involved 30 mice divided into five groups: negative control (placebo), positive control (placenta extract), and three banana stem extract gel treatment groups (15%, 20%, 25%). Wounds were made on the mice and treated daily, with images and tissues taken on specific days. **Results:** Banana stem extract gel resulted in faster wound healing, with increased collagen density on day 14, especially in the 25% concentration treatment group. Comparison between groups showed significant differences in collagen density with a P Value of 0.034 (P Value 0.05), highlighting the potential of banana stem extract gel as a wound healing agent. **Conclusion:** *Punti lasse* (*Musa acuminata* var. *punti lasse* AAA) stem extract gel with 25% concentration can significantly increase collagen density in the healing process of incisional wounds in female mice (*Musculus*) for 14 days.

**Keywords:** Wound, Collagen, *Punti Lasse*.

## INTRODUCTION

A wound is the loss or destruction of part of the body's tissue caused by sharp or blunt trauma, temperature changes, chemical exposure, explosion, electric shock, or animal bites (1,2). Wounds can cause damage to the protective function of the skin due to loss of continuity of epithelial tissue with or without damage to other tissues, such as muscle, bone and nerves (3). Wound healing is an important process in the recovery of the human body after injury or trauma (4,5). It involves various complex stages, including inflammation, cell proliferation, extracellular matrix synthesis and tissue remodelling (6,7). The wound healing process involves various stages, one of which is collagen formation (8). Collagen is the main protein in the extracellular matrix that provides structure and strength to connective tissue (9,10). During the wound healing process, fibroblasts produce collagen that forms scar tissue to replace damaged tissue (11). The density and organisation of collagen in the scar tissue will affect the strength and elasticity of the healed wound (12).

Common wounds in women are perineal wounds, these wounds often occur in the process of childbirth, which is a condition of damage or loss of tissue components in the vulva around the vaginal introitus and anus (13). Perineal wounds are divided into two types, namely episiotomy wounds and spontaneous wounds (ruptures) (14). Episiotomy wounds are caused by surgical procedures performed to enlarge the birth

canal to facilitate the delivery process, while spontaneous wounds occur naturally without surgical intervention due to excessive pressure during labour (15). Perineal wounds need attention because they can cause dysfunction of female reproductive organs such as bleeding, infection which may cause death due to bleeding or sepsis, and in the long term can interfere with maternal comfort in terms of sexual intercourse (16,17). To prevent the onset of infection or other complications in the puerperium, especially with perineal rupture, it can be done by improving the quality of health services, including intensive perineal wound care. (18).

The incidence of perineal rupture in women giving birth in the world in 2020 was 2.7 million cases, which is expected to reach 6.3 million by 2050. In Asia alone, 50% of labouring women experience perineal rupture. (18). In 2019 maternal deaths in Indonesia were 4,221 cases, the most maternal deaths were caused by bleeding (1,280 cases) (19). In 2020, the incidence of perineal rupture among women in labour in Indonesia was 83% vaginal delivery, found from a total of 3,791 women who gave birth spontaneously vaginally. Approximately 80% of mothers received perineal sutures, 42% due to episiotomy and 38% due to spontaneous tears. In developing countries the main causes of maternal mortality are direct obstetric factors, namely postpartum haemorrhage, infection and eclampsia. (18). The wound healing process is influenced by several factors, such as the use of medications and nutritional intake. (20). The use of drugs for wound healing can be done with the use of herbal medicine (21). Many herbal medicines are derived from natural ingredients, one of the natural ingredients that has attracted attention is banana stem extract (*Musa acuminata* var. *punti lasse AAA*) (22-24). This extract has long been used in traditional medicine for various diseases, and several studies have shown its potential in improving wound healing, either through anti-inflammatory activity, antimicrobial activity, or increased collagen production (24,25).

The part of the banana plant that is used for wound healing treatment is the sap (26). The results of phytochemical screening on banana plant stems contain flavonoids, ascorbic acid, saponins, triterpenoids, steroids, alkaloids and tannins. Saponins and flavonoids have the potential to heal wounds (27). (227). In addition to banana sap, banana fruit is used to heal wounds to the intestines. (228). *The* use of banana plant leaves to dress wounds avoids infection and exposure to microorganisms (227). Local culture and customary provisions owned by the community will form a wise and wise traditional knowledge including in terms of medicine. Indonesia already has such traditional knowledge, one of which is the use of banana stem sap as an alternative medicinal ingredient. (21).

The utilisation of banana stem sap has been part of the hereditary tradition of the Indonesian people, especially in rural areas such as Enrekang, to treat cuts that often occur while working in the garden. However, research related to the effect of banana stem extract on collagen density in wound healing is still limited, as well as its comparison with other wound healing agents such as placenta extract which has been proven effective in accelerating the healing process. This study aims to evaluate the effectiveness of banana stem extract in increasing collagen density in the wound healing process using female mice as an experimental animal model. It is hoped that this study can provide a deeper understanding of the potential of banana stem extract in wound healing, as well as strengthen the scientific basis for the development of more effective and sustainable wound healing therapies.

## METHODOLOGY

**Research Type:** This study is a pure research (true experimental) with post-test only control group design, using female mice (*Mus musculus*) as subjects. Mice weighing 20-35grams were divided into five groups: negative control (placebo), positive control (placenta extract), and three treatment groups with banana stem extract gel concentrations of 15%, 20%, and 25%. Adaptation was performed for 6 days prior to treatment, with wound care and image collection performed on days 1, 3, 5, 8, and 12. Wound tissue collection was performed on days 7 and 14.

**Place and Time of Research:** The preparation of banana stem extract was carried out in the Biopharmaca laboratory of Almarisa Madani University, while laboratory tests were carried out in the laboratory of Minasa Mitra Medika Main Clinic. The study was conducted from January to April 2024, allowing sufficient time for the extraction and analysis process.

**Population and Research Sample:** The population used was adult female mice (*Mus musculus*), with a total sample size of 30 mice divided into 5 groups. The sampling technique used the Federer formula, ensuring an adequate sample size for accurate analysis.

### Research Instruments:

- 1. Tools:** Camera, cage, pet food, sterile gloves, surgical tools, sterile mask, shaver, 10 ml syringe, cotton swabs, *cotton buds*.
- 2. Materials:** Female mice, Banana stem extract gel (15%, 20%, 25%), Placenta extract (Bioplacenton Gel), placebo, 70% alcohol, 10% buffered formalin.

**Data Collection:** The study began with animal preparation, where 30 female mice (*Mus musculus*) weighing between 20-35grams were randomly selected. Prior to treatment, the mice underwent adaptation for 6 days to reduce potential stress. The banana stems used in the study were obtained from Patongloan Village, Baroko District, Enrekang Regency, South Sulawesi. The process of making banana stem extract was carried out with careful steps, starting from cleaning the banana stem from dirt, then cut into thin slices and dried using an oven at 70°C for 3 days. The dried banana stems were ground into powder, then extracted using 96% ethanol solvent for 3x24 hours. After filtering and separating from the solvent, the extract was stored in a closed and dark container to protect it from sunlight. Next, banana stem extract gels were prepared in three preparations with concentrations of 15%, 20%, and 25%, respectively, using additional ingredients such as carbopol, propylenglycol, TEA, DMDM, and distilled water. The gel manufacturing process involved meticulous measuring and mixing of ingredients to ensure consistency and stability. Mice were then prepared for the experiment by shaving their fur and performing aseptic technique before a standardised incision wound was made. Each group of mice was treated according to their category, with incision wound care and photography performed daily, and wound tissue collection performed on days 7 and 14 for histopathological examination in the laboratory. The entire process was carefully conducted and documented to ensure the validity and consistency of the study results.

**Research Permission and Ethical Clearance:** This study was approved by the Research Ethics Committee of FKM Hasanuddin (Protocol No. 31124092046). The 3R principle (Replacement, Reduction, Refinement) was applied to ensure humane treatment of the experimental animals.

**Operational Definition:** Banana gum extract is operationalised as an extract produced from dried banana stems and extracted using 96% ethanol through maceration process, with the dose given according to the diameter of the wound. Bioplacentol Gel is operationalised as a gel applied topically on the wound with the dose also adjusted to the wound diameter. Collagen was operationalised as a fibrous protein that provides elasticity and is the most important component of connective tissue, as measured by histopathological tests.

**Data Processing and Analysis:** Data were more than 2 groups and not normally distributed, so data management used *Mann Whitney* test and *Kruskal Wallis* test to see the difference in collagen density in each group, namely the negative control group, positive control group, and banana stem extract gel group 15%. 20%. 25%.

## RESULTS AND DISCUSSION

### Results

Research on the effectiveness of Punti Lasse stem extract gel (*Musa acuminata* var. *punti lasse* AAA) on increasing collagen density in the wound healing process of female mice (*Mus musculus*) was conducted from January to April 2024. The sample consisted of 30 female mice divided into 5 treatment groups, including the negative control group, positive control, and treatment groups with Punti Lasse stem extract gel in concentrations of 15%, 20%, and 25%. Phytochemical test results showed that banana stem contains flavonoids, saponins, phenolic compounds, and terpenoids.

### Average Body Weight of Female Mice

**Table 1: Mean Body Weight of Female Mice (*Musculus*) in Each Group**

Treatment Group	N	Mean
Negative Control (Placebo)	6	30,00
Positive Control (Placenta Extract)	6	29,50
15% EBP gel	6	25,67
20% EBP Gel	6	27,33
25% EBP gel	6	28,83
Total	30	28,27

Source: Primary Data 2024

Table 1 shows that the average body weight of mice in the negative control group (placebo) is 30.00 grams, in the positive control group (placenta extract) is 29.50 grams, 15% EBP gel group is 25.67 grams, 20% EBP gel group is 27.33 grams and 25% EBP gel group is 28.83 grams. The total mean body weight of the five groups of experimental animals was 28.27 grams.

### Average Wound Healing

**Table 2: Mean macroscopic wound healing (Nagaoka scoring)**

Treatment Group	Healing Time (days)	Healing score	Localised infection	Allergic Reaction
Negative Control (Placebo)	9,5	2	3	3
Positive Control (Placenta Extract)	7	3	3	3
15% EBP gel	9,5	2	3	3
20% EBP Gel	8,16	2	3	3
25% EBP gel	7,33	2	3	3

Source: Primary Data 2024

Based on Table 2, the average wound healing based on the dragonoka score showed that the positive control group and 25% EBP Gel had a wound healing time of 7 and 7.33 days. Negative control and 15% EBP Gel had a wound healing time of 9.5 days, and 20% EBP Gel had a wound healing time of 8.16 days. For local infection and allergic reaction, each group scored 3.

### Degree of Wound Healing in Histopathological Test

**Table 3: Mean wound healing with collagen density parameters in day 7 and day 14**

Treatment Group	Collagen Day 7	Collagen Day 14	P Value*
Negative Control (Placebo)	1	1,67	<b>0,025</b>
Positive Contour (Placenta Extract)	2,67	3	0,317
15% EBP gel	1	2	0,068
20% EBP Gel	1,33	2,67	0,099
25% EBP Gel	1,33	3	<b>0,034</b>
<b>P Value**</b>	<b>0,047</b>	<b>0,022</b>	

\*Mann Whitney Test

\*\*Kruskal Wallis Test. Significant P Value <0.05

Source: Primary Data, 2024

Based on table 3. wound healing with collagen density parameters on days 7 and 14, there were differences between the five treatment groups on collagen density, namely the negative control group there was a significant difference (P Value 0.025), positive control, 15% EBP Gel, and 20% EBP Gel there was no significant difference (P Value 0.317), (P Value 0.068), (P Value 0.099), and the 25% EBP Gel contro showed a significant increase in collagen density with a P Value of 0.034 (P value <0.05).

Collagen density based on the score of the assessment group was followed by *Kruskal Walis* test to see the increase in collagen between groups on days 7 and 14. The results obtained that most affected the density on day 14 showed a P value of 0.022, (P value <0.05) which means there is a significant difference between collagen density on day 14.

### Comparison of Collagen Density Between Groups

**Table 4: Comparison between positive control group and banana stem extract gel.**

Group	n	Day 7		Day 14	
		Mean Rank	P Value*	Mean Rank	P Value*
Positive Control	3	5.00	<b>0.034</b>	5.00	<b>0.034</b>
Negative Control	3	2.00		2.00	
Positive Control	3	5.00	<b>0.034</b>	5.00	<b>0.025</b>
15% EBP gel	3	2.00		2.00	
Positive Control	3	4.83	0.068	4.00	0.317
20% EBP Gel	3	2.17		3.00	
Positive Control	3	4.83	0.068	3.50	1.000
25% EBP gel	3	2.17		3.50	

Source: Primary Data, 2024

Based on table 4. comparison between collagen density on day 7, positive control with negative control obtained P Value 0.034 (P Value <0.05) which means there is a significant difference, positive control with 15% EBP Gel obtained P Value 0.034 (P



Value <0.05) which means there is a significant difference, positive control with 20% EBP Gel obtained P Value 0.068 (P Value>0.05) which means there is no significant difference, positive control with 25% EBP Gel obtained P Value 0.068 (P Value>0.05) which means there is no significant difference.

Comparison between collagen density on day 14, positive control with negative control obtained P Value 0.034 means there is a significant difference, positive control with 15% EBP Gel obtained P Value 0.025 means there is a significant difference, positive control with 20% EBP Gel obtained P Value 0.317 means there is no significant difference and positive control with 25% EBP Gel obtained P Value 1.000 no significant difference.

### Degree of Wound Healing in Histopathology Test with Re-Epithelialisation Parameters

**Table 4.5: Mean wound healing on days 7 and 14 with Re-epithelialisation parameters**

GROUP	Re-epithelialisation	
	Day-7	Day 14
Negative Control (Placebo)	1	2
Positive Control (Placenta Extract)	2.33	2,67
15% EBP gel	1.67	2
20% EBP Gel	1.67	2
25% EBP gel	1.67	2

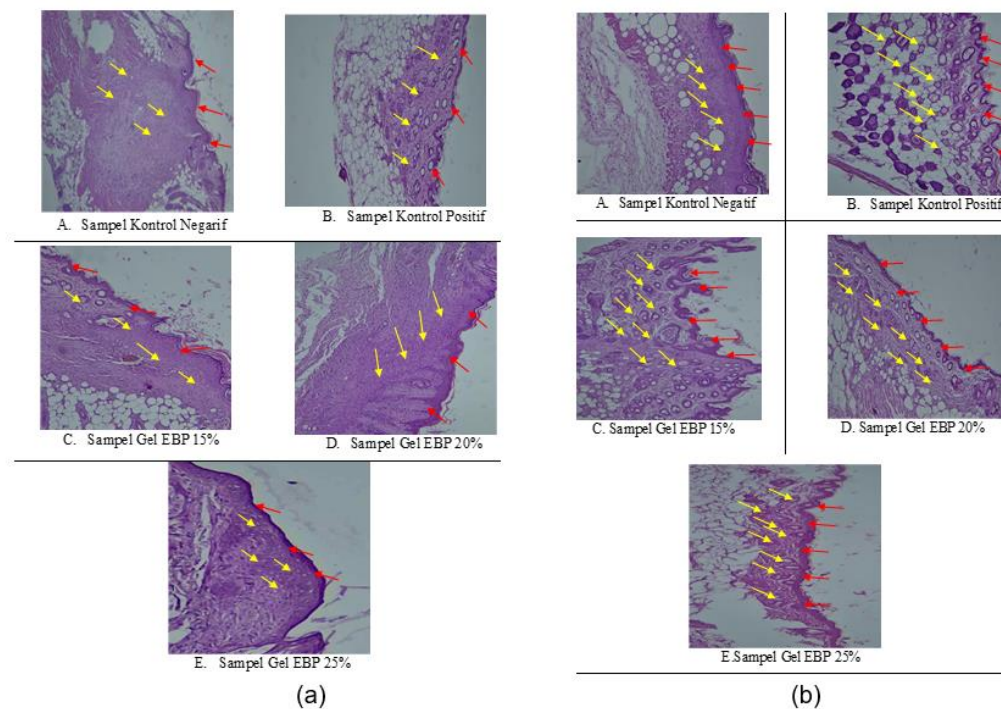
Source: Primary Data, 2024

Based on table 5 on day 7 epithelialised tissue in the negative control has a score of 1 (not all fused), positive control has a score of 2.33 (fused but not the same thickness), 15% EBP Gel, 20% EBP Gel and 25% EBP Gel has a score of 1.67 (not all fused). On day 14 epithelialised tissue in the negative control had a score of 2 (fused but not the same thickness), positive control had a score of 2.67 (fused but not the same thickness), 15% EBP Gel, 20% EBP Gel and 25% EBP Gel each had a score of 2 (fused but not the same thickness).

### Histopathological Test Results

Figure 1(a) illustrates collagen formation and re-epithelialisation in the skin of female mice after administration of EBP gel on day 7. Five conditions are shown: (A) thin collagen and epithelialised tissue that has not fused completely, (B) thick collagen with fused epithelialised tissue of equal thickness, (C) thin collagen with fused epithelialised tissue but uneven thickness, (D) thin collagen with epithelialised tissue that has not fused completely, and (E) medium collagen with fused epithelialised tissue but uneven thickness. Image magnification is 100X.

Figure 1(b) illustrates collagen formation and re-epithelialisation in the skin of female mice after EBP gel administration on day 14. The five conditions shown are: (A) medium collagen with fused tissue epithelialisation but uneven thickness, (B) dense collagen with fused tissue epithelialisation of equal thickness, (C) medium collagen with fused tissue epithelialisation but uneven thickness, (D) dense collagen with fused tissue epithelialisation but uneven thickness, and (E) dense collagen with fused tissue epithelialisation but uneven thickness. Image magnification is 100X.



**Figure 1**

## DISCUSSION

The process of wound healing and tissue repair is a complex process involving a series of dynamic events (29). The initial response when a wound or injury occurs is inflammation which aims to stop bleeding and prevent infection, followed by the proliferation or fibroplasia phase as the initial marker of collagen formation (30). Fibroblasts proliferate and synthesise collagen, which is needed for tissue repair. Collagen is the main component of extra-cellular tissue, which maintains integrity, structure and strength (lasting 2-3 weeks) (31). The success of the proliferation process determines the outcome of the maturation process. The maturation process is the end of the wound healing process. The wound healing process is terminated by the formation of 50-80% scar tissue that has the same strength as the previous tissue and is not accompanied by any signs of infection. (32).

From the results of macroscopic observation (dragonoka scoring), it was found that the group with faster wound healing time was the Positive Control Group (7 days) and 25% EBP Gel (7.33 days). EBP Gel 20% (8.16 days), while Negative Control and EBP Gel 15% (9.5 days). Based on histopathological tests with *hematoxylin eosin* (HE) staining, 100X magnification that has been done on wound tissue treated with Negative Control (Placebo), Positive Control (Placenta Extract), 15% EBP Gel, 20% EBP Gel and 25% EBP Gel for 7 and 14 days, the data was obtained using *Mann Whitney test and Kruskal Wallis test*.

The results obtained showed that collagen density increased after the administration of 25% EBP Gel for 14 days with a P Value of 0.034 (P Value <0.05) with a score of 3 (formed dense collagen). In line with previous researchers explaining significant wound healing activity with banana stem extracts (33)

Comparison between positive control groups (Placenta Extract) with banana stem extract gel (EBP Gel), it was found that the positive control with negative control was significant where on day 7 P Value 0.034 and on day 14 P Value 0.034. Positive control with 15% EBP Gel on day 7 P Value 0.034 and day 14 P Value 0.025 there is a significant difference. Positive control with 20% EBP Gel on day 7 P Value 0.068 and day 14 P Value 0.317 there is no significant difference. Positive control with 25% EBP Gel day 7 P Value 0.068 and day 14 P Value 1.000 there is no significant difference.

Consistently, the treatment groups that received EBP gel, especially at a concentration of 25%, showed a shorter wound healing time span compared to the control group. In addition, histopathological analysis showed a significant increase in collagen density in the 25% EBP Gel treatment group, signifying the important role of this gel in improving tissue structure and accelerating the healing process. However, despite this, there was no significant difference in re-epithelialisation between treatment groups, suggesting that the effect of EBP Gel may be more focused on the process of tissue regeneration rather than epithelial regeneration. In addition, there were no signs of local infection or excessive allergic reactions in the treatment groups, confirming that the use of EBP Gel is safe and tolerated by the body. Nonetheless, it should be kept in mind that this study was conducted in mice, and further studies in more complex animal models as well as human clinical trials are needed to confirm these findings and understand the underlying mechanism of action in more detail. Thus, EBP gel may be a promising candidate to be developed as an effective and safe wound healing therapy in humans, but further studies are needed to validate these findings before widespread clinical application.

Phytochemical screening of banana stem extract obtained from Enrekang contains flavonoids, saponins, terpenoids and phenolic compounds. The ability of banana stem extract gel (EBP Gel) in the wound healing process is due to the banana stem containing these phytochemical compounds. Flavonoid and saponin compounds in banana stem spur collagen formation, which accelerates the wound healing process and provides tensile strength to the healed wound (27). Various researchers have shown that plants containing flavonoids, saponins, terpenoids, phenolics promote wound healing due to their astrigenic, antioxidant and antimicrobial properties (34-36). This study is in line with previous research by administering plantain stem extract (*Musa paradisiaca L*), where the re-epithelialisation period was significantly reduced (day 12). (37) (38).

Based on the description above, the researcher's assumption in this study is that banana stem extract that has been formulated in the form of a gel preparation has an effect on the healing process of incision wounds in mice, so that it can be used as one of the external medicinal therapies for perineal *ruptures*.

**Limitations of the Study:** This study has not directly compared with other wound healing agents, such as placenta extract. Therefore, more extensive and comprehensive follow-up studies are needed to validate these findings and develop more effective wound healing therapies.

**Research Conclusion:** Puntii lasse stem extract gel (*Musa acuminata* var.puntii lasse AAA) with a concentration of 25% can significantly increase collagen density in the healing process of incision wounds in female mice (*Musculus*) for 14 days.

**Conflict of interest:** None



## References

- 1) Wintoko R, Yadika ADN. Current Management of Wound Care. *Journal of Medicine, University of Lampung*. 2020;4:183-89.
- 2) Vachhrajani V, Khakhkhar P. *Science of wound healing and dressing materials*. Singapore: Springer; 2020.
- 3) Marcelino N, Girsang E, Nasution AN, Ginting CN. Effectiveness Of Ethanol Extract Gel Of Leaf Leaves Of *Cymbopogon Nardus L* Against Grade I A Burn-In White Rats (*Rattus Norvegicus*). *International Journal of Health and Pharmaceutical (IJHP)*. 2022 Jun 26;2(3):557-65.
- 4) Tottoli EM, Dorati R, Genta I, Chiesa E, Pisani S, Conti B. Skin wound healing process and new emerging technologies for skin wound care and regeneration. *Pharmaceutics*. 2020 Aug 5;12(8):735.
- 5) Yang F, Bai X, Dai X, Li Y. The biological processes during wound healing. *Regenerative medicine*. 2021 Apr;16(04):373-90.
- 6) Potekaev NN, Borzykh OB, Medvedev GV, Pushkin DV, Petrova MM, Petrov AV, Dmitrenko DV, Karpova EI, Demina OM, Shnayder NA. The role of extracellular matrix in skin wound healing. *Journal of Clinical Medicine*. 2021 Dec 18;10(24):5947.
- 7) El Ayadi A, Jay JW, Prasai A. Current approaches targeting the wound healing phases to attenuate fibrosis and scarring. *International journal of molecular sciences*. 2020 Feb 7;21(3):1105.
- 8) Masson-Meyers DS, Andrade TA, Caetano GF, Guimaraes FR, Leite MN, Leite SN, Frade MA. Experimental models and methods for cutaneous wound healing assessment. *International journal of experimental pathology*. 2020 Feb;101(1-2):21-37.
- 9) Mienaltowski MJ, Gonzales NL, Beall JM, Pechanec MY. Basic structure, physiology, and biochemistry of connective tissues and extracellular matrix collagens. *Progress in Heritable Soft Connective Tissue Diseases*. 2021:5-43.
- 10) Halper J. Basic components of connective tissues and extracellular matrix: fibronectin, fibrinogen, laminin, elastin, fibrillins, fibulins, matrilins, tenascins and thrombospondins. *Progress in heritable soft connective tissue diseases*. 2021:105-26.
- 11) Mathew-Steiner SS, Roy S, Sen CK. Collagen in wound healing. *Bioengineering*. 2021 May 11;8(5):63.
- 12) Sullivan JV, Myers S. Skin structure and function, wound healing and scarring. In: *Plastic Surgery-Principles and Practice*. Elsevier; 2022 Jan 1. pp. 1-14.
- 13) Childs C, Sandy-Hodgetts K, Broad C, Cooper R, Manresa M, Verdú-Soriano J. Birth-related wounds: risk, prevention and management of complications after vaginal and caesarean section birth. *Journal of wound care*. 2020 Nov 1;29(Sup11a):S1-48.
- 14) Puissegur A, Accoceberry M, Rouzair M, Pereira B, Herault M, Bruhat C, Delabaere A, Gallot D. Risk Factors for Perineal Wound Breakdown in Early Postpartum: A Retrospective Case-Control Study. *Journal of Clinical Medicine*. 2023 Apr 21;12(8):3036.
- 15) Choudhari RG, Tayade SA, Venurkar SV, Deshpande VP, CHOUDHARI RG, Tayade S, Deshpande V. A review of episiotomy and modalities for relief of episiotomy pain. *Cureus*. 2022 Nov 17;14(11).
- 16) Hu Y, Lu H, Huang Q, Ren L, Wang N, Huang J, Yang M, Cao L. Risk factors for severe perineal lacerations during childbirth: A systematic review and meta-analysis of cohort studies. *Journal of Clinical Nursing*. Jul 2023;32(13-14):3248-65.
- 17) Bertrand K, Lefevre JH, Creavin B, Luong M, Debove C, Voron T, Chafai N, Tiret E, Parc Y. The management of perineal hernia following abdomino-perineal excision for cancer. *Hernia*. 2020 Apr;24:279-86.
- 18) Jayanti, Ili dwi, and Jennifer Brier. "Factor Analysis of Perineal Rupture in Maternity Mothers at Puskesmas Sobang Banten District in 2022." *Malaysian Palm Oil Council (MPOC)*. 2022;21(1):1-9.
- 19) Ministry of Health of the Republic of Indonesia. *Indonesia Health Profile 2019*. Jakarta: Ministry of Health of the Republic of Indonesia; 2019.

- 20) Gushiken LF, Beserra FP, Bastos JK, Jackson CJ, Pellizzon CH. Cutaneous wound healing: An update from physiopathology to current therapies. *Life*. 2021 Jul 7;11(7):665.
- 21) Monika P, Chandraprabha MN, Rangarajan A, Waiker PV, Chidambara Murthy KN. Challenges in wound healing: role of complementary and alternative medicine. *Frontiers in nutrition*. 2022 Jan 20;8:791899.
- 22) Kumar N, Ved A, Yadav RR, Prakash O. A comprehensive review on phytochemical, nutritional, and therapeutic importance of *Musa*. *International Journal of Current Research and Review*. 2021 May;13:114-24.
- 23) Yadav A. Banana (*Musa acuminata*): Most popular and common Indian plant with multiple pharmacological potentials. *World Journal of Biology Pharmacy and Health Sciences*. 2021;7(1):036-44.
- 24) Dash A, Majhi T, Ratha S, Mishra SP, Pradhan B. Phytochemical and Antimicrobial Aspects of Wild *Musa balbisiana* and *Musa acuminata*.
- 25) Warowicka A, Nawrot R, Goździcka-Józefiak A. Pharmacologically active compounds from latex-bearing plants. In *Advances in botanical research 2020 Jan 1* (Vol. 93, pp. 119-151). Academic Press.
- 26) Maseko KH, Regnier T, Meiring B, Wokadala OC, Anyasi TA. *Musa* species variation, production, and the application of its processed flour: A review. *Scientia Horticulturae*. 2024 Feb 1;325:112688.
- 27) Cahyanto T, et al. Ethnobotany Study of Banana Plant Sap (*Musa* Sp.) as an Incision Remedy (*Vulnus Scissum*). *Biosphere*. 2020;13(1):28-41. doi: 10.21009/biosferjpb.v13n1.28-41.
- 28) Umadevi MU, Sampath KPK, Bhowmik D, Duraivel S. Traditional. *Mangroves and Salt Marshes*. 2012;2(3):133-48. doi: 10.1023/A:1009988607044.
- 29) Tottoli EM, Dorati R, Genta I, Chiesa E, Pisani S, Conti B. Skin wound healing process and new emerging technologies for skin wound care and regeneration. *Pharmaceutics*. 2020 Aug 5;12(8):735.
- 30) Lux CN. Wound healing in animals: a review of physiology and clinical evaluation. *Veterinary dermatology*. 2022 Feb;33(1):91-e27.
- 31) Wang H. A review of the effects of collagen treatment in clinical studies. *Polymers*. 2021 Nov 9;13(22):3868.
- 32) Shedoeva A, et al. Wound Healing and the Use of Medicinal Plants. *Evidence-Based Complementary and Alternative Medicine*. 2019 Sep. doi: 10.1155/2019/2684108.
- 33) Amutha K, Selvakumari U. Wound Healing Activity of Methanolic Stem Extract of *Musa Paradisiaca* Linn. (Banana) in Wistar Albino Rats. *International Wound Journal*. 2016;13(5):763-67. doi: 10.1111/IWJ.12371.
- 34) Vitale S, Colanero S, Placidi M, Di Emidio G, Tatone C, Amicarelli F, D'Alessandro AM. Phytochemistry and biological activity of medicinal plants in wound healing: an overview of current research. *Molecules*. 2022 Jun 1;27(11):3566.
- 35) Baidoo MF, Mensah AY, Ossei PP, Asante-Kwatia E, Amponsah IK. Wound healing, antimicrobial and antioxidant properties of the leaf and stem bark of *Entada africana* Guill. & Perr. *South African journal of botany*. 2021 Mar 1;137:52-9.
- 36) Rahman MM, Rahaman MS, Islam MR, Hossain ME, Mannan Mithi F, Ahmed M, Saldías M, Akkol EK, Sobarzo-Sánchez E. Multifunctional therapeutic potential of phytocomplexes and natural extracts for antimicrobial properties. *Antibiotics*. 2021 Sep 6;10(9):1076.
- 37) Weremfo A, et al. Wound Healing Potential of *Musa Paradisiaca* L. (*Musaceae*) Stem Juice Extract Formulated into an Ointment. *Research J. Pharmacology and Pharmacodynamics*. 2018;3(6):294-96.
- 38) Saputra YF, et al. Identification of Secondary Metabolite Compounds in the Heart of Cotton Banana (*Musa x Paradisiaca* L.). *Journal of Chemistry and Chemical Education*. 2022;11(3):1-5.