

## EVALUATION OF THE WOUND HEALING EFFICACY OF THE FORMULATED BIOMATERIAL DRESSING IN THE ANIMAL MODEL

K. Dhanalakshmi <sup>1</sup>, P K Ananthakumar <sup>2</sup>, Raghu Babu Pothireddy <sup>3</sup>,  
T. Mary Vergheese <sup>4\*</sup>, Angeline Julius <sup>5</sup>, Archana Behera <sup>6</sup> and  
Mukesh Kumar Dharmalingam Jothinathan <sup>7</sup>

<sup>1</sup> Department of Chemistry, Madras Christian College,  
East Tambaram, Chennai, Tamil Nadu, India.

<sup>2</sup> Department of General Medicine, Saveetha Medical College and Hospitals,  
Saveetha Institute of Medical and Technical Sciences (SIMATS),  
Saveetha University, Chennai, India.

<sup>3</sup> Acadicell Innovations International Pvt. Ltd.,  
Peerakankaranai, Vandalur, Chennai, Tamil Nadu, India.

<sup>4</sup> Guru Nanak College, Velachery, Chennai, Tamil Nadu, India.

<sup>5</sup> Centre for Materials Engineering and Regenerative Medicine,  
Bharath Institute of Higher Education and Research, Chennai, Tamil Nadu, India.

<sup>6,7</sup> Centre for Global Health Research, Saveetha Medical College and Hospitals,  
Saveetha Institute of Medical and Technical Sciences (SIMATS),  
Saveetha University, Chennai, India.

Email: <sup>4</sup>maryvergheese@mcc.edu.in (\*Corresponding Author), <sup>7</sup>itsmemukesh@gmail.com

DOI: [10.5281/zenodo.12649907](https://doi.org/10.5281/zenodo.12649907)

### Abstract

Wounds are characterized as the breakup of the tissue's anatomical and cellular continuity, brought on by chemical, physical, or immunological factors. While the wound healing process involves restoration of the integrity of the damaged tissue, chronic wounds present a significant problem to both the patient and the doctor. Selection of appropriate wound dressings accelerates the healing process, especially in the case of nonhealing wounds it is crucial to find the appropriate therapeutic method to improve the patient's well-being. In recent times, nanoparticles have gained importance for their anti-microbial and wound-healing effects. Our study involves the incorporation of the seed husk extract of psyllium doped silver nanoparticles (AgNps) in combination with the Human Amniotic Membrane (HAM) to use as a wound dressing in a full-thickness biopsy punch model in Wistar Albino Rats. The wound closure percentage was analyzed, and histopathological studies were performed. The results demonstrated the efficient wound repair and regenerative activity of formulated wound dressing in comparison to the control concluding its efficiency in *In vivo* studies.

**Keywords:** Wound Healing, Wound Dressing, Human Amniotic Membrane, Psyllium, Silver Nanoparticles, Wistar Albino Rats.

### INTRODUCTION

The process of wound healing is intricate, involving a series of well-coordinated physiological and molecular events. These events unfold in a specific sequence, including hemostasis, inflammation, migration, proliferation, tissue remodelling, and maturation. Various cell types play crucial roles in regulating these events (Nagar et al., 2016). Wound healing can be classified based on its pathogenesis and outcomes. Acute wounds progress through a series of molecular events that ultimately restore structural integrity. Conversely, chronic wounds do not resolve as expected and are characterized by persistent pathological processes. The four phases of wound healing occur in a precise and sequential manner, culminating in the remodeling phase where granulation tissue is replaced by scar tissue. In chronic wounds, however, the inflammatory phase often persists, resulting in compromised and delayed healing.

In chronic wounds, the immune response is characterized by persistent inflammation, largely driven by an abundance of pro-inflammatory macrophages. These macrophages often struggle to efficiently clear dead neutrophils, causing accumulation of tumour necrosis factor- $\alpha$  and interleukin- $1\beta$ . Additionally, they release various matrix metalloproteinases (MMPs), which degrade the extracellular matrix and hinder the onset of the proliferative phase of wound healing (Raziyeva et al., 2021). In addition to inflammation, chronic wounds commonly face challenges related to infection. Infection arises when the immune system and cells are unable to eradicate harmful microorganisms within the wound. These infections can manifest as local, spreading, or systemic, with the severity determining the necessary course of treatment (Verdolino et al., 2021).

The healing duration of wounds varies significantly between acute and chronic types. Acute wounds typically heal within a time frame of 8 to 12 weeks, while chronic wounds lack a definitive healing timeline (Rezvani Ghomi et al., 2019). Chronic wounds are categorized into six types distinguished by specific parameters including granulation, slough, and necrotic tissue. This classification system enables treatment tailored to the underlying etiology, incorporating a systemic assessment of associated comorbidities, thereby assisting physicians in predicting outcomes (Popescu et al., 2023).

The management of chronic wounds relies on principles that not only aim to alleviate or eliminate the underlying causes but also addresses metabolic imbalances such as disease or infection. Effective wound care begins with comprehensive patient and wound assessments in the initial stages (Frykberg & Banks, 2015). The concept of wound bed preparation encompasses an understanding of the wound matrix, which may be compromised and unable to support epidermal migration. Consequently, wound care clinicians typically address the first three components before assessing the wound edge for signs of epidermal cell migration. The incorporation of the epidermal edge led to the development of the acronym "TIME," meaning Tissue, Inflammation, Moisture and Epidermis serving as a clinical tool for managing chronic wounds (Schultz et al., 2004).

Later, the 'E' in the acronym was revised to represent the Edge of the wound, specifically for non-advancing or undermined areas. This adjustment reflected the recognition that the failure of epidermal migration is often related to issues with the extracellular matrix or cells at the wound edge (Schultz et al., 2003).

Choosing the appropriate wound dressing is paramount for accelerating wound healing, reducing treatment costs, and enhancing overall patient well-being. An ideal wound dressing should shield the wound from the complex environment, prevent adherence to the wound, minimize pain, maintain a moist wound bed, control exudates, and safeguard the surrounding skin (Britto EJ et al., 2024). Recent research supports the efficacy of various modern dressings and skin substitutes in wound treatment. In this regard, our research focuses on the utilization of the Human Amniotic Membrane (HAM) as a source of skin substitute. HAM possesses numerous biological properties that facilitate wound healing, attributed to the presence of growth factors, cytokines, chemokines, and other regulatory molecules. Particularly in chronic wounds, HAM has demonstrated significant epithelialization (Castellanos et al., 2017). In our approach, the wound-healing properties of HAM are combined with the antimicrobial effects of silver nanoparticles (AgNps) (Yin et al., 2020) and the gel-

forming capabilities of Psyllium (Masood & Miraftab, 2010). This synergistic combination aims to reduce infection, provide moisture, and serve as a source of skin substitute to promote wound healing.

In this study, the final formulated product was pre-clinically tested with Wistar rats wherein we created a wound model using an excision biopsy punch and compared the effects of the final product with other materials used in this study. We observed the percentage of wound closure, and these results of the animal studies are also supported by the histopathological examination of the animal tissue.

## MATERIALS AND METHODS

### Animals

The study adhered to ethical standards, obtaining clearance before commencement. Wistar Albino rats (n=3) were housed in standard laboratory conditions and utilized for in vivo assays. Rats, aged 90 days old and weighing approximately 200–250 grams, were selected for the study. They were provided with a standard laboratory diet in pellet form, along with access to drinking water ad libitum.

### Creation of excision biopsy punch

ketamine (40 mg/kg body weight) and xylazine (15 mg/kg body weight) combinations were administered intramuscularly on the dorsal side of the rats after a clean shave. An excision biopsy punch was then used to create an 8 mm diameter excision wound by passing through the lifted midline.

### Cases and Treatment of Animals

Three different cases of treatment were used with controls as follows:

Case (i): Psyllium with silver nanoparticles vs control (non-treated)

Case (ii): Control (Non-treated) vs Amniotic Membrane with Psyllium & silver nanoparticles

Case (iii): Psyllium with silver nanoparticles vs Amniotic Membrane with Psyllium and silver nanoparticles

### Assessment of wound healing

The wound closure was measured using a vernier calliper after the end of the study period. The wounds were measured and photographed. The wound closure percentage was calculated using the formula given below:

$$\% \text{ of Wound Closure} = \frac{(\text{Initial wound measurement} - \text{wound measurement at time X})}{\text{Initial Wound measurement}} * 100$$

Following the wound creation, rats were administered a single shot of amoxicillin (0.001 ml/kg body weight), and with piroxicam (3 mg/kg body weight), the anti-inflammatory agent, intramuscularly for three days. Throughout the initial two days, the rats were closely monitored for any signs of active infection. The animals were euthanized and the wound area was excised and fixed with 10% neutral buffered formalin for subsequent histopathological examination after the study period.

## Histopathological preparation and visualization

Histopathology study involves the following 4 processes for visualization of the tissue with a light microscope (Eclipse E600-Nikon). For the process of fixation, 10% formalin was used as a fixative agent.

The effect of formalin is to cross-link the membrane proteins by forming covalent bonds thus maintaining the shape and structure of the cells/tissue. The next step is the Paraffin Embedding where the paraffin replaces the water in the tissue. This is done through dehydration, clearing, and embedding.

The next step is Sectioning wherein the paraffin blocks of tissue are cut into thin sections, here in the range of 3 – 10 microns, using a rotary microtome. This is followed by the final step – staining, wherein the slides are stained with hematoxylin/eosin (H&E) and the sample is analyzed under a light microscope to visualize the tissue structure and intact epithelial layer.

## RESULTS

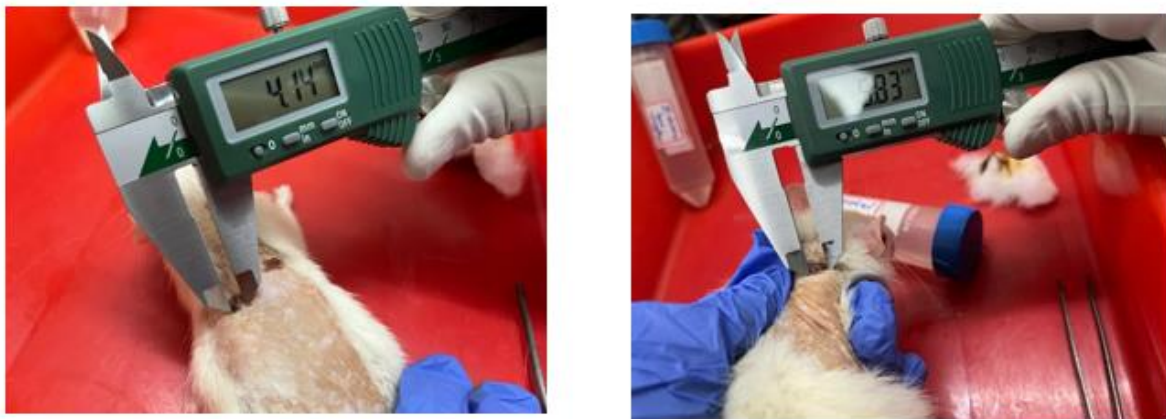
### Formulation of the wound dressing

The *In vitro* studies showed effective results in the treatment of the cells with the fixed concentrations of products that are used in this study as mentioned below:

The amniotic membrane was made into powder form and 2 mg was used. Along with it, 1 mg of psyllium powder was mixed with 10 µg of AgNPs. The individual components and formulation of all these components were used as the treatment options for the wounds created in the rats.

### Results of the Animal Studies:

Case (i): Psyllium with silver nanoparticles vs control (non-treated)



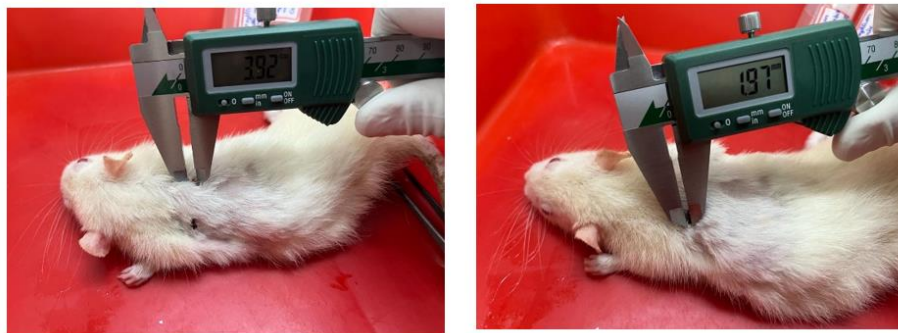**Figure 1: Wound closure measurement is measured using a vernier calliper. The image on the left shows the case of a wound treated with Psyllium & silver nanoparticles and on the right is a non-treated wound.**

Case (ii): Control (Non-treated) vs Amniotic Membrane with Psyllium & silver nanoparticles



**Figure 2: Wound closure measurement is measured using a vernier calliper. The image on the left shows the case of a non-treated wound and on the right is the wound treated with Amniotic Membrane combined with Psyllium & Silver nanoparticles.**

Case (iii): Psyllium with silver nanoparticles vs Amniotic Membrane with Psyllium and silver nanoparticles

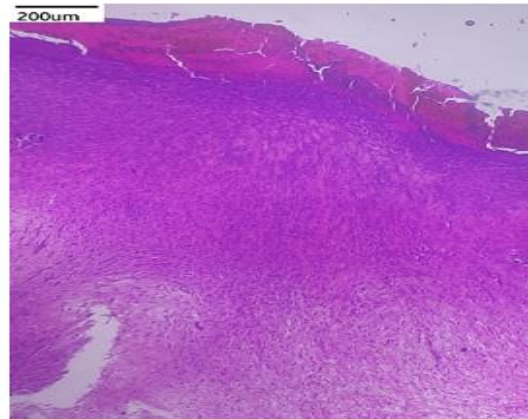


**Figure 3: Wound closure measurement is measured using a vernier calliper. The image on the right shows the case of a wound treated with amniotic membrane combined with Psyllium & silver nanoparticles and on the left is the wound treated with Psyllium & Silver nanoparticles.**

**Table 1: Wound closure percentage in Wistar Albino rats treated with different cases After the wound closure was observed, the animal tissue was excised to its full depth and the tissue was given to histological examination. The results of the histopathological studies are as follows:**

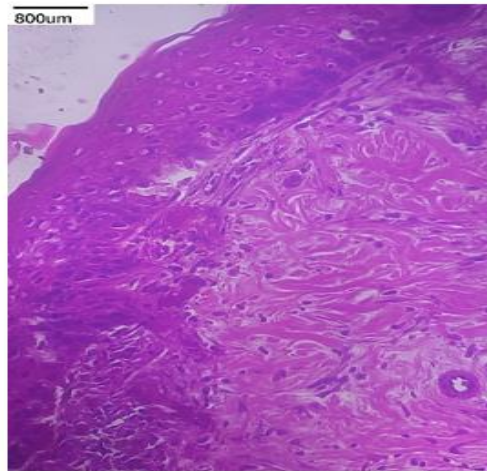
Cases	Initial wound measurement at 0 <sup>th</sup> day (mm)	Wound measurement at the end of study period (mm)	Wound Closure (%)
Case i - non-treated	8	5.83	27.12
Case i - Psyllium with AgNp	8	4.14	48.25
Case ii – non-treated	8	5.67	29.12
Case ii - Membrane with Psyllium & AgNp	8	2.01	74.87
Case iii - Psyllium with AgNp	8	3.92	51
Case iii - Membrane with Psyllium & AgNp	8	1.97	75.37

**Control (Non – treated):**



**Figure 4: Histopathology examination of the control (non-treated) wound**

**Test 1: Psyllium with AgNps:**



**Figure 5: Histopathology examination of the wound treated with the combination of Psyllium & AgNps**

**Test 2: Membrane with Psyllium & AgNps:**



**Figure 6: Histopathology examination of the wound treated with Membrane, Psyllium & AgNps.**

Images of H&E staining tissues that were taken from the sites of the wound are depicted above. The control group exhibited many inflammatory cells whereas the other cases showed minimal inflammation. Overall, the skin at the wound sides in cases except the control group remained intact. In the context of the fibroblast arrangement, disorder arrangement was seen in the case of the control group and regular arrangement in the other groups.

## DISCUSSION

Chronic wounds do not heal easily and have a predictable amount of time. According to a survey conducted by Arun Bal et al., various chronic wounds and the age group of patients affected by it were concluded. Also, the survey highlights the need for affordable treatment options and awareness among individuals for the treatment and management of chronic wounds (Bal et al., 2023). Studies on the clinical use of the amniotic membrane have been reported for over a century but have not been used to their fullest. However, advancements in tissue processing and preservation techniques have yielded commercially available membrane grafts. The amniotic membrane exhibits anti-inflammatory properties and is a reservoir of various growth factors that are involved in tissue growth and regeneration also termed wound healing (Zelen M & Serena, 2015). Silver therapy has many benefits including antibacterial properties on cells by reducing the organism's chances of developing resistance. Also, literature suggests that the silver nanoparticles are inexpensive, safe and exhibit antibacterial effects by interacting with the bacteria's peptidoglycan cell wall and plasma membrane, bacterial DNA and its proteins (Gunasekaran et al., 2011). Studies have demonstrated a significant increase in the mean % wound contraction when Psyllium was formulated as ointment and applied topically (Singh et al., n.d.). Combining the effects of the compounds as mentioned above; in our study, we doped the psyllium with silver nanoparticles and then combined it with the human amniotic membrane.

As per the results of the *In vivo* studies that are mentioned above, the different cases and treatment methods showed positive results of wound healing thus proving the wound healing effect of the various components used. In case (i), the wound closure percentage is higher in the wound treated with the psyllium-doped silver nanoparticles when compared with that of the non-treated (control) case. Similar results are observed in case (ii), where the closure percentage is higher with the treatment done by Amniotic membrane in combination with the psyllium-doped silver nanoparticles when compared to the non-treated wounds. This is on par with the results of case (iii), where the treatment with the final formulated product shows 75.37% wound closure.

The results of the histopathology examination showed the following in the case of the control/non-treated group (Fig. 4), the skin showed evidence of disrupted stratum corneum with no layers of stratum granulosum and the stratum basale appears to be irregular and obliterated. Dense granulations and white blood cells are present indicating the process of healing at a slow pace (Wilkinson & Hardman, 2020). Another distinctive feature that was observed here, is the improper establishment of the epidermis and dermis which suggests significant damage and ongoing repair mechanisms. (Rittié, 2016) Considering the skin tissue obtained from the wound site treated with Psyllium and silver nanoparticles (Fig 5), a mature epidermal layer is seen exhibiting the presence of both stratum corneum and stratum granulosum. The layer of stratum spinosum is continuous from top to bottom indicating a healthy cellular turnover with a regular arrangement of stratum basale. Scarce granulations are

present suggesting near completion of the healing process (Maynard & Downes, 2019). The epidermis and dermis layer are distinct and clear indicating the restored integrity and proper structural organization.(Farage et al., 2013) With the Wound treated with Amniotic Membrane combined with Psyllium and silver nanoparticles, the skin at the wound site exhibits clear arrangements of all the layers – stratum corneum, granulosum, spinosum and basale, indicating completely restored structural integrity. In addition to it, the absence of granulations and the presence of skin appendages suggest complete healing of the skin. (Evans et al., 2013)

## CONCLUSION

Comparing and correlating the results of the wound closure percentage and the respective results of the histopathological examination showed promising evidence in *In vivo* studies wherein complete wound healing and restoration of structural integrity along with distinctive separate layers was observed in the case of the wounds treated with the Amniotic Membrane along with the combination of Psyllium and AgNPs. Thus, we can conclude that the formulated wound dressing: A combination of Amniotic membrane, Psyllium and silver nanoparticles is an effective biocompatible wound dressing to treat acute and chronic wounds.

## References

- 1) Bal, A., Vaidya, S., & Parakh, R. (2023). Assessment of chronic wound patients' journey in India: a survey of the perspectives of healthcare professionals and patients.
- 2) Britto EJ, Nezwek TA, & Robins M. (2024). *Wound Dressings*. Star Pearls Publishing.
- 3) Castellanos, G., Bernabé-García, Á., Moraleda, J. M., & Nicolás, F. J. (2017). Amniotic membrane application for the healing of chronic wounds and ulcers. *Placenta*, 59, 146–153. <https://doi.org/10.1016/j.placenta.2017.04.005>
- 4) Evans, N. D., Oreffo, R. O. C., Healy, E., Thurner, P. J., & Man, Y. H. (2013). Epithelial mechanobiology, skin wound healing, and the stem cell niche. *Journal of the Mechanical Behavior of Biomedical Materials*, 28, 397–409. <https://doi.org/10.1016/j.jmbbm.2013.04.023>
- 5) Farage, M. A., Miller, K. W., Elsner, P., & Maibach, H. I. (2013). Characteristics of the Aging Skin. *Advances in Wound Care*, 2(1), 5–10. <https://doi.org/10.1089/wound.2011.0356>
- 6) Frykberg, R. G., & Banks, J. (2015). Challenges in the Treatment of Chronic Wounds. *Advances in Wound Care*, 4(9), 560–582. <https://doi.org/10.1089/wound.2015.0635>
- 7) Gunasekaran, T., Nigusse, T., & Dhanaraju, M. D. (2011). Silver Nanoparticles as Real Topical Bullets for Wound Healing. *Journal of the American College of Clinical Wound Specialists*, 3(4), 82–96. <https://doi.org/10.1016/j.jcws.2012.05.001>
- 8) Masood, R., & Miraftab, M. (2010). Psyllium: Current and Future Applications. In *Medical and Healthcare Textiles* (pp. 244–253). Elsevier. <https://doi.org/10.1533/9780857090348.244>
- 9) Maynard, R. L., & Downes, N. (2019). The Skin or the Integument. In *Anatomy and Histology of the Laboratory Rat in Toxicology and Biomedical Research* (pp. 303–315). Elsevier. <https://doi.org/10.1016/B978-0-12-811837-5.00024-1>
- 10) Nagar, H. K., Srivastava, A. K., Srivastava, R., Kurmi, M. L., Chandel, H. S., & Ranawat, M. S. (2016). Pharmacological Investigation of the Wound Healing Activity of *Cestrum nocturnum* (L.) Ointment in Wistar Albino Rats. *Journal of Pharmaceutics*, 1–8. <https://doi.org/10.1155/2016/9249040>
- 11) Popescu, V., Cauni, V., Petrutescu, M. S., Rustin, M. M., Bocai, R., Turculeț, C. R., Doran, H., Patrascu, T., Lazar, A. M., Crețoiu, D., Varlas, V. N., & Mastalier, B. (2023). Chronic Wound Management: From Gauze to Homologous Cellular Matrix. *Biomedicines*, 11(9), 2457. <https://doi.org/10.3390/biomedicines11092457>



- 12) Raziyeva, K., Kim, Y., Zharkinbekov, Z., Kassymbek, K., Jimi, S., & Saparov, A. (2021). Immunology of Acute and Chronic Wound Healing. *Biomolecules*, 11(5), 700. <https://doi.org/10.3390/biom11050700>
- 13) Rezvani Ghomi, E., Khalili, S., Nouri Khorasani, S., Esmaeely Neisiany, R., & Ramakrishna, S. (2019). Wound dressings: Current advances and future directions. *Journal of Applied Polymer Science*, 136(27). <https://doi.org/10.1002/app.47738>
- 14) Rittié, L. (2016). Cellular mechanisms of skin repair in humans and other mammals. *Journal of Cell Communication and Signaling*, 10(2), 103–120. <https://doi.org/10.1007/s12079-016-0330-1>
- 15) Schultz, G. S., Barillo, D. J., Mazingo, D. W., & Chin, G. A. (2004). Wound bed preparation and a brief history of TIME. *International Wound Journal*, 1(1), 19–32. <https://doi.org/10.1111/j.1742-481x.2004.00008.x>
- 16) Schultz, G. S., Sibbald, R. G., Falanga, V., Ayello, E. A., Dowsett, C., Harding, K., Romanelli, M., Stacey, M. C., Teot, L., & Vanscheidt, W. (2003). Wound bed preparation: a systematic approach to wound management. *Wound Repair and Regeneration*, 11(s1). <https://doi.org/10.1046/j.1524-475X.11.s2.1.x>
- 17) Singh, S., Singh, R., Kumar, N., & Kumar, R. (n.d.). 2011. Wound healing activity of ethanolic extract of *Plantago ovata* (Ispaghula) seeds. *Journal of Applied Pharmaceutical Science*, (07), 108–111.
- 18) Verdolino, D. V., Thomason, H. A., Fotticchia, A., & Cartmell, S. (2021). Wound dressings: curbing inflammation in chronic wound healing. *Emerging Topics in Life Sciences*, 5(4), 523–537. <https://doi.org/10.1042/ETLS20200346>
- 19) Wilkinson, H. N., & Hardman, M. J. (2020). Wound healing: cellular mechanisms and pathological outcomes. *Open Biology*, 10(9). <https://doi.org/10.1098/rsob.200223>
- 20) Yin, I. X., Zhang, J., Zhao, I. S., Mei, M. L., Li, Q., & Chu, C. H. (2020). The Antibacterial Mechanism of Silver Nanoparticles and Its Application in Dentistry. *International Journal of Nanomedicine*, 15, 2555–2562. <https://doi.org/10.2147/IJN.S246764>
- 21) Zelen M, C., & Serena, T. (2015). *Amniotic Membrane: Can It Facilitate Healing?*