

# ANESTHESIA OF CRANIOTOMY-SURGERY IN REMOVAL TUMOR OF LEFT GIANT PARASAGITTAL MENINGIOMA PATIENTS: A CASE REPORT

M. Mukhlis Rudi Prihatno <sup>1\*</sup> and Dhoni Amalia Arbaeni <sup>2</sup>

<sup>1</sup> Medical Faculty of Jenderal Soedirman University.

\*Corresponding Author Email: [rudianestesi@gmail.com](mailto:rudianestesi@gmail.com)

<sup>2</sup> Residence of Anesthesiology, Medical Faculty of Jenderal Soedirman University.  
Email: [dhoniarbaeni@gmail.com](mailto:dhoniarbaeni@gmail.com)

DOI: [10.5281/zenodo.12731723](https://doi.org/10.5281/zenodo.12731723)

## Abstract

Meningioma is a persistent benign extra-axial idiopathic tumor originating from arachnoid cap cells in the outer layer of the leptomeninges and may occur anywhere arachnoidal cells are found. Anesthetic management of the neurosurgical patient requires an understanding of the physiologic implications of the surgical procedure. A 48-year-old male presented with complaints of headache and loss of both visions one year before admission to the hospital. He had a progressively dull headache for two months, which was more severe in the morning and relieved for a short time after getting analgetic. He was admitted; brain contrast and non-contrast Computerized Tomography (CT) revealed a giant left parasagittal tumor, probably meningioma, measuring approximately 6.6 cm × 5.6 cm × 7.1 cm. The deviation of the midline to the right was about 2 - 2.5 cm. An increase in intracranial pressure was seen in brain CT. The patient was diagnosed with left giant parasagittal meningioma. The optimal conditions for meningioma tumor surgery are challenging for anesthetists to minimize edema and bleeding. A wide variety of medications are available for general anesthesia management. Therefore, the anesthetist must know the effects of each drug used to maintain the patient's hemodynamic condition and achieve a flaccid state of the brain tissue.

**Keywords:** Giant Meningioma, Parasagittal Meningioma, Neuroanesthesia.

## 1. INTRODUCTION

Meningioma is a persistent benign extra-axial idiopathic tumor that originates from arachnoid cap cells in the outer layer of the leptomeninges and may occur anywhere arachnoidal cells are found [1-3]. These tumors often occur in multiple locations where arachnoid cells are present between the brain and bone, the ventricles, and along the spine (Eissa et al., 2020; Richard et al., 2019; Sanai et al., 2010). These lesions can occur at any age, most commonly in older people. Meningioma incidence in women is higher than in men, with a 2:1 intracranial ratio and 10:1 in the spine (Ogasawara et al., 2021; Rock et al., 2018). The giant-sized meningioma may invade the vital neurovascular surrounding structure, making surgery technically challenging. The tumor can grow large in an area with maximal compliance before becoming symptomatic. Headache, papilledema, and visual deterioration are the manifestations of this tumor. Complete visual loss can be developed. Papilledema can be followed later by secondary optic atrophy. Giant meningioma is considered a tumor with more than 5 cm in size (Narayan et al., 2018).

Anesthetic management of the neurosurgical patient requires an understanding of the physiologic implications of the surgical procedure. Goals include adequate cerebral oxygenation and perfusion, intracranial pressure (ICP) reduction, and stable hemodynamics. The anesthetics should also permit electrophysiological monitoring. Anesthetic techniques that allow for rapid and complete recovery of consciousness,

facilitating early evaluation of neurological status, are especially desirable (Hussein et al., 2022).

General anesthesia is the most commonly used technique for craniotomy, although the procedure may be performed awake for some specific indications. Usually, general craniotomy anesthesia requires optimal operative conditions, stable systemic and cerebral hemodynamics, adequate analgesia and ventilation, and rapid recovery for neurocognitive testing or response (Hussein et al., 2022). Intravenous anesthesia that can reduce ICP and CBF from induction drug classes are pentothal, propofol, etomidate, and midazolam. Inhalation anesthetic techniques have been widely accepted in neurosurgical management, but they can decrease vascular resistance, particularly cerebral vascular resistance, resulting in increased CBF and ICP. In cases with increased ICP, the inhalation anesthetic technique will make the ICP higher, thereby reducing CPP and increasing the risk of cerebral ischemia, which can cause brain damage (Nguyen et al., 2023).

## 2. CASE REPORT

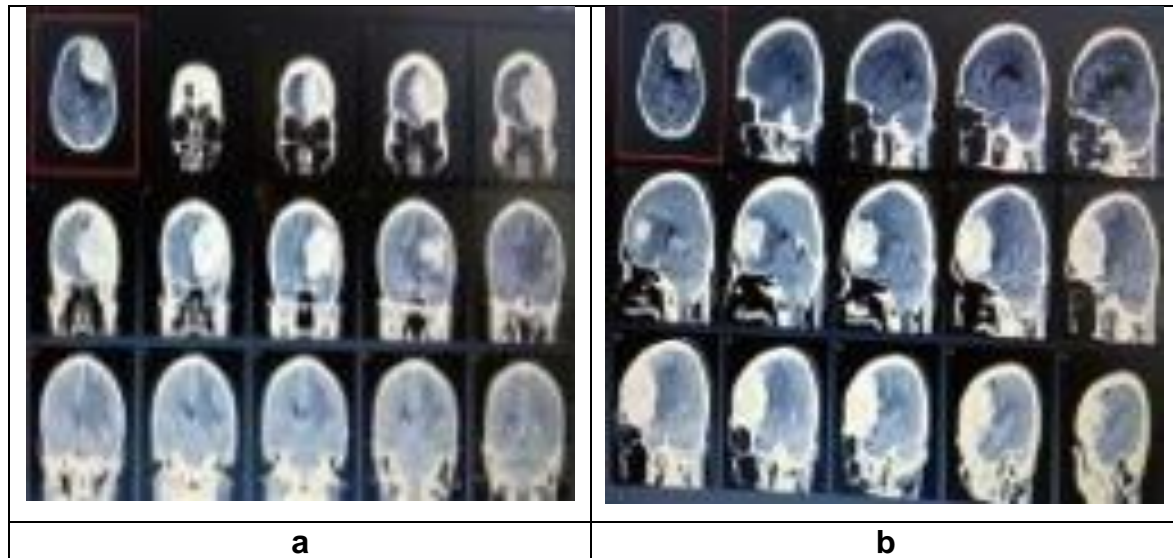
A 48-year-old male presented with complaints of headache and loss of both visions one year before admission to the hospital. He had a progressively dull headache for two months, which was more severe in the morning and relieved for a short time after getting an analgesic. He could walk as well as run. His speech had not changed, and no history of seizures. History of high blood pressure and diabetes mellitus was denied. A history of asthma and allergies to food and drugs was also rejected. Systemic examination was unremarkable. On physical exam, patient with a blood pressure of 118/67 mmHg, a regular pulse rate of 78 beats/minute, a breath rate of 20 times/minute, and an oxygen saturation of 99% on room air. He had no fever, with a temperature of 36.5°C.

Mallampati 1, good flexion and extension movements of the neck and temporomandibular joints. The ophthalmic, ear, nose, and throat (ENT) evaluation was unremarkable. Auscultation of the chest, the lungs, and vesicular breath sounds, no wheezing and rhonchi were found. Cor was normal in auscultation, no gallop or murmur. All routine laboratory investigations were regular. Chest radiograph with a posterior-anterior position is normal limits. Electrocardiography (ECG) with a 90 times/minute heart rate of sinus rhythm. He was admitted; brain contrast and non-contrast Computerized Tomography (CT) revealed a giant left parasagittal tumor, probably Meningioma, measuring approximately 6.6 cm × 5.6 cm × 7.1 cm (Figure 1). The deviation of the midline to the right was about 2 - 2.5 cm. An increase in intracranial pressure was seen in brain CT. The patient was diagnosed with left giant parasagittal Meningioma.

His airway assessment was Mallampati I, and his physical status, according to the American Society of Anesthesiologists (ASA) classification, was class II. Relevant aspects of anesthesia and perioperative care were explained to the patient, and informed consent was obtained. Two units of packed red cells were typed and cross-matched for intraoperative use.

On arrival at the theatre, the patient's identity was confirmed. Standard routine monitors were attached, and the capnograph was calibrated. His baseline vital signs were a 72 beats/minute pulse rate, BP 112/60 mmHg, and SPO<sub>2</sub> 100% on room air. The patient had 2 IV lines (both peripheral) and an arterial line. Intravenous

ondancetrone 4 mg and dexamethasone 10 mg were administered before the induction of anesthesia.



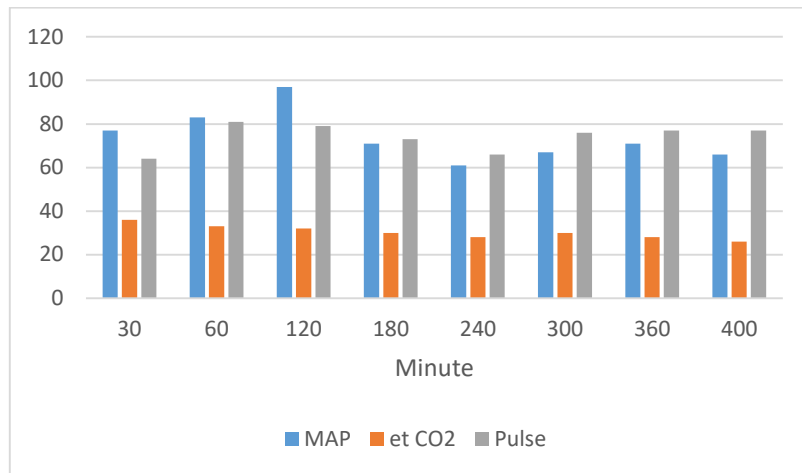
**Figure 1: Contrast computerized tomography (CT) scan (a. coronal), (b. sagittal)**

Following preoxygenation with 100% oxygen, intravenous Sufentanyl 15 micrograms and thiopental 250 mg were administered as induction agents. At the loss of the eyelash reflex, intravenous rocuronium (50 mg) was administered while deepened with sevoflurane 2%. The trachea was intubated with a size 7.5 mm cuffed armored tube, and correct placement was confirmed with capnograph tracing and chest auscultation. Automated intermittent positive pressure ventilation was instituted. Anesthesia was maintained with 60%, 40% oxygen, air, and 0.8 to 1.2% isoflurane vapor. A total fresh gas flow of 3 liters per minute was administered. Muscle relaxation was maintained by a continuous syringe pump of intravenous rocuronium 20 mg/hour. The blood pressure and pulse rate were recorded every 5 minutes at the end of the surgical procedure. Foley's urethral catheter was passed to monitor hourly urine output.

The patient was supine positioned and cradled on a May field horseshoe headrest. Intravenous 20% mannitol 200ml and furosemide 40 mg was given before the bone flap was raised. Analgesia was maintained by continuous syringe pump of intravenous dexmedetomidine 20 mcg/hour.

Monitoring durante procedure was done by evaluating NIBP, systolic and diastolic arterial blood pressure, end-tidal carbon dioxide (CO<sub>2</sub>), oxygen saturation, and ECG wave (Figure 2). The arterial oxygen saturation was between 99% and 100%. The ECG showed normal sinus rhythm. The intraoperative vital sign was a pulse rate of 64-81 beats/minute, while systolic and diastolic blood pressure of NIBP ranged between 77-107 mmHg and 42-68 mmHg. Also, systolic and diastolic arterial blood pressure ranged between 78-115 mmHg and 47-67 mmHg, respectively. End-tidal carbon dioxide (EtCO<sub>2</sub>) was between 29 mmHg and 36 mmHg. Urine output through a urine catheter. The estimated total intraoperative blood loss was 800 ml, and the diuresis was 2800 ml. Patients received 6400ml of crystalloid. When the periosteum is opened, the dura does not appear tense, and a slack brain occurs when the dura is opened. The patient was not transfused of blood because the allowable blood loss

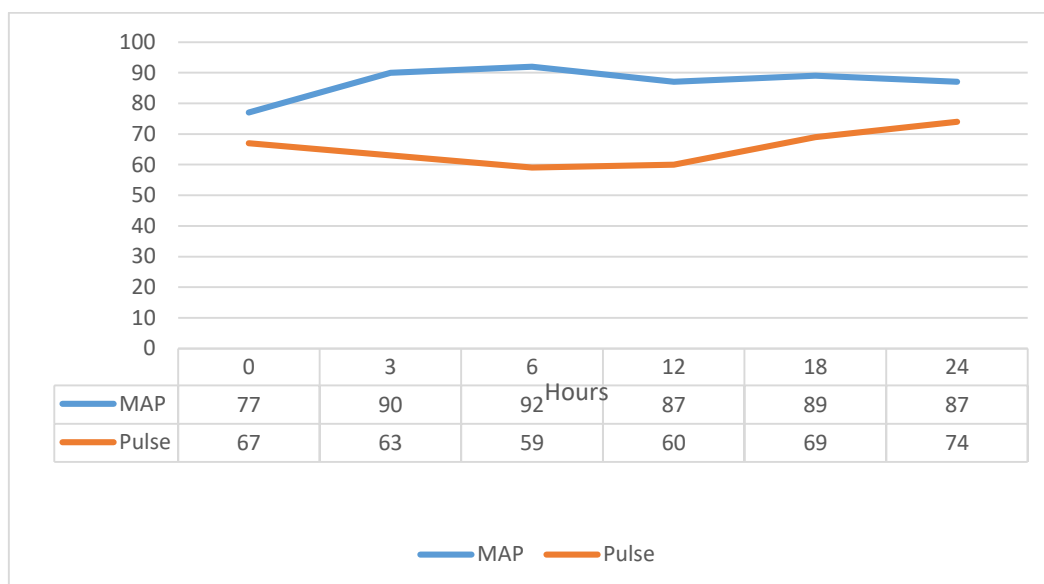
was 2630 ml. The tumor was excised, the dura mater and the bone were thrown away, and other layers were closed until the operation was complete.



**Figure 2: Monitoring Haemodinamics durante operation**

At the end of the procedure which lasted 6 hours isoflurane was turned off; muscle relaxant and analgetic continuous was turned off. The patient has been intubated and transferred to the ICU with monitoring of SPO<sub>2</sub> 100%; pulse rate 72 beats/minute and BP 112/75 mmHg.

Patient entered the ICU on ventilator control (assisted control, FiO<sub>2</sub> 80%, respiratory rate 10 times/min, P-inspiration 12, PEEP 5, VT 420-560 cc, Oxygen saturation (SaO<sub>2</sub>) 100%). While in the ICU, patient was monitoring (Figure 3). After 12 hours in ICU, weaning ventilator in spontan mode, and was extubated.



**Figure 3: Monitoring Haemodinamics in ICU**

### 3. DISCUSSION

Meningiomas are solid tumors that are usually firmly attached by a broad base to the dura, accounting for between 15 to 20% of primary intracranial tumors (Ogasawara et al., 2021). The tumor location, growth rate, and raised ICP may be responsible for its

clinical manifestations. The index patient had hemiparesis due to the tumor mass effect on the motor area. The progressive involvement of the pyramidal system may also explain the hypertonia and brisk reflexes of the lower limbs. Most of the meningioma grows slowly, and complaints and disorders result from pressure on the area around the mass. The giant-sized meningioma may invade the vital neurovascular surrounding structure, making surgery technically challenging. The tumor can grow to a large size in an area with maximal compliance before it is symptomatic. Giant meningioma is considered a tumor with more than 5 cm in size. Headache, papilledema, and visual deterioration are the manifestations of this tumor. Complete visual loss can be developed. Papilledema can be followed later by secondary optic atrophy. Visual disturbances occur in a predictable pattern according to the location of the mass to the optic nerve, optic tract, optic radiation, and visual cortical area (Hafez et al., 2015; Ogasawara et al., 2021; Richard et al., 2019; Sanai et al., 2010).

The three most common complaints are headache, altered mental status, and limb weakness. Most meningioma can be treated surgically, especially if the tumor location allows for complete extraction of the tumor and is accompanied by dura layer adhesions (Eissa et al., 2020; Narayan et al., 2018; Richard et al., 2019).

The general classification of meningioma based on the World Health Organization (WHO) criteria divides meningioma into three groups, as shown in Table 1 (Hafez et al., 2015). All of these factors influence prognosis and management strategies.

**Table 1: Meningioma grading based on the WHO criteria**

Type	Characteristic
Benign meningioma (WHO Grade I)	Histological variant other than the clear cell, chordoid, papillary, or rhabdoid
Atypical meningioma (WHO Grade II) any of three criteria	Lack criteria of atypical and anaplastic meningioma Mitotic index $\geq$ four mitoses/10 high-power field (HPF) Brain invasion At list 3 of 5 parameters: Increase cellularity High nuclear/cytoplasmic ratio (small cells) Prominent nucleoli Uninterrupted pattern-less or sheet-like growth The fact of spontaneous necrosis (i.e., not induced by embolization or radiation)
Anaplastic (malignant)	Mitotic index $\geq$ 20 mitoses/10 high-power field

Neoplasms in the central nervous system can cause both generalized and focal neurological disorders. Patients with tumors causing increased ICP may experience headache, nausea and vomiting, ataxia, syncope, and visual and cognitive impairments (Narayan et al., 2018). Focal neurological signs are presented due to the mass compression in the surrounding area. Evaluation of a patient suspected of having an intracranial mass begins with the history and neurological examination. Radiological examination is essential for determining the patient's diagnosis and location of the tumor and postoperative assessment of patients with a supra-tentorial period (Ogasawara et al., 2021).

CT scan is a dependable tool in the diagnosis of space occupying lesions but Magnetic resonance imaging (MRI) where available is the gold standard. Both imaging modalities were employed in the course of the management of the index patient (Ogasawara et al., 2021; Pasternak, 2022).

Preoperative control of intracranial hypertension and correction of co-morbid conditions improves surgical outcome. Several things are essential to avoid during surgery, namely, hypoxemia, hypercapnia, anemia, and hypotension because they will harm the central nervous system and surgery results. Hypoxia and hypercarbia can also exacerbate ICP and this can be avoided by ensuring a patent airway and adequate ventilation. It is essential to maintain brain autoregulation and response to CO<sub>2</sub> to prevent ICP. Cerebral blood flow (CBF) is maintained at a mean arterial pressure (MAP) of 50–150 mmHg. Exceeding this limit, even with maximal dilation or maximal constriction of the cerebral blood vessels, CBF will passively follow the cerebral perfusion pressure (CPP). If CBF is significantly reduced (MAP <50 mmHg), cerebral ischemia can occur. Above normal limits (MAP >150 mmHg), the pressure will damage the constriction of blood vessels, and CBF will rise suddenly. There is damage to the blood-brain barrier, and there is cerebral edema and possible cerebral hemorrhage (Hussein et al., 2022; Rock et al., 2018). Autoregulation of blood flow to the brain under normal conditions ranges from 50cc/100 g/min with a basal brain oxygen consumption of 3.3cc/100 g/min and a glucose consumption of 4.5 mg/100 g/min. This condition can occur when the MAP is maintained between 50 and 150 mmHg. MAP below 50 mmHg can cause ischemia in brain tissue, while pressures above 150 mmHg will cause damage to the blood-brain barrier resulting edema or severe bleeding. In the case of brain tumor removal, a target PaO<sub>2</sub> of 100–200 mmHg is expected. The provision of high oxygen levels with a PaO<sub>2</sub> >200 mmHg should be avoided because cerebral vasoconstriction can occur and cause brain tissue ischemia (Jf, 2013; Nguyen et al., 2023; Rock et al., 2018). Changes in the partial pressure of CO<sub>2</sub> in the arteries (PaCO<sub>2</sub>) will result in changes in brain blood flow because CO<sub>2</sub> is a potent vasodilator in brain blood vessels. Every mmHg change in PaCO<sub>2</sub> between 25 and 80 mmHg will change brain blood flow by about 4%. In brain tumor surgery, the PaCO<sub>2</sub> is maintained between 25 and 30 mmHg to decrease CBF. PaCO<sub>2</sub> pressures below 20 mmHg should be avoided as they can cause severe vasoconstriction and cause brain tissue ischemia (Andrzejowski & Fraser, 2010).

The efficacy of steroids in reducing the edema associated with tumors is widely documented. Administration of steroids for 48 hrs before an elective surgical procedure has the potential to reduce edema formation and improve the clinical condition by the time of craniotomy. Steroids are usually administered intraoperatively and postoperatively to maintain the effects achieved by preoperative treatment (Rehatta et al., 2019). In this case, a steroid was administered before induction.

The reduction in brain volume can also be achieved by maintaining high serum osmolality. This forms the basis for the use of intravenous mannitol for acute reduction of brain volume (Zhang et al., 2019). Furosemide, a loop diuretic, is slower in onset and less reliable than mannitol, but its action appears synergistic. Our patient benefitted from the use of both agents.

Prior research has shown that between the propofol and thiopental groups in suppressing the hemodynamic response after induction of general anesthesia, there was a significant difference only at the first minute in diastolic blood pressure. As for diastolic blood pressure, mean arterial pressure and heart rate were not found to be significantly different. Propofol and thiopental were used as part of the anesthetic management of the patient. Thiopental decreases cerebral metabolic rate (CMRO<sub>2</sub>), CBF, and ICP. The effect of propofol on CMRO<sub>2</sub> and CBF is similar to that of thiopental, but recovery from propofol is faster and has no hang-over effect

(Aitkenhead et al., 2007). Thiopental was considered to be beneficial for neurosurgical patients because it preserves autoregulation of cerebral blood flow (CBF) and decreases intracranial pressure (ICP) by reducing cerebral metabolic oxygen consumption and CBF. The degree of central nervous system depression induced by barbiturates ranges from mild sedation to unconsciousness, depending on the dose administered (Jf, 2013). The induction dose of thiopental is 3-6 mg/kg. In this case, 250mg of thiopental is used for induction, weighing 50 kg.

Once anesthetized, a train of four measurements may be calibrated before administering muscle relaxant and then sequentially monitored to ensure full paralysis prior to laryngoscopy. Adequate depth of paralysis is important to further reduce the risk of eliciting airway responses, such as coughing, that may increase ICP. Quantitative neuromuscular monitoring enables titration and rationalization of muscle relaxant doses to ensure reversal prior to measurement of motor evoked potential (MEP) (Andrzejowski & Fraser, 2010). In this case, the train of four was not measured because of no tools. Muscle relaxants are known to increase CBF, but the agents that increase CBF the least are vecuronium and rocuronium, so they are the drugs of choice for neuroanaesthesia. In this case, 50 mg of rocuronium bromide was given to facilitate intubation. Rocuronium was chosen in this case because it is the competitive muscle relaxant that has the fastest onset of action, reportedly reacting within 2 min with an intermediate duration of action.

The low blood/gas coefficient of sevoflurane (conferring titratability) plus the following properties proffer favorability in the neurosurgical setting: rapid onset, rapid offset, and nondistinctive disturbance of cerebral hemodynamics. High concentrations of sevoflurane (>1.5 MAC) may impair autoregulation of CBF, thus allowing a drop in CBF during hemorrhagic hypotension (Jf, 2013). For deepened induction, we used sevoflurane 2%.

The maintenance of inhalation anesthesia used isoflurane 0.8% - 1.2% with a ratio of 60% oxygen and 40% air. 60% oxygen flow is used to prevent the PaO<sub>2</sub> pressure above 200 mmHg. Isoflurane produces a dose-dependent cerebral vasodilation with a reduction of cerebral metabolic rate. It increases cerebral blood flow (CBF) and intracranial pressure by blunting cerebral autoregulation. However, at < 1 MAC values, there is only a modest decrease in CBF and CO<sub>2</sub> responsiveness. At low or high concentrations, isoflurane causes no change in the rate of cerebrospinal fluid (CSF) formation and resistance to resorption of CSF. At doses approaching 1 MAC, the EEG frequency decreases. With isoflurane, burst suppression appears on EEG at about 1.5 MAC, and electrical silence happens at 2 MAC. Isoflurane does not evoke seizure activity on EEG (Jf, 2013; Pasternak, 2022).

The maintenance of analgetic, in this case, used dexmedetomidine. Dexmedetomidine is used for analgo-sedation during neurosurgical procedures. Dexmedetomidine administration produces sedation and anxiolysis, thought to be mediated by its inhibitory effect on noradrenergic neurons in the locus coeruleus, but has a minimal impact on respiratory drive. The sedative effects are unique, as an arousable sedation state is induced, similar to natural sleep. It causes peripheral vasoconstriction and has a direct effect on the smooth vascular muscle. The overall cardiovascular effects are complex, with modest heart rate and blood pressure declines at lower blood concentrations but bradycardia and hypertension at higher concentrations. The drug favors cerebral hemodynamics, reducing cerebral blood flow and maintaining flow-

metabolism coupling. In addition to mild analgesic effects, it has also been shown to potentiate the analgesic effects of opioids. The mechanism of dexmedetomidine protecting the brain may be related to the levels of dexmedetomidine promoting nerve injury factors and inflammation factors. Dexmedetomidine has other advantageous effects in neurosurgical patients, such as reducing postoperative opioid consumption and pain [16-20].

We combined intravenous and inhalational anesthesia instead of choosing one technique because the drug-like propofol does not provide enough effect for 3 hours of surgery. We did not extubate this patient because we wanted to avoid problems when transferring the patient to the ICU. The goals in postoperative neuro-critical care are to maintain the CPP adequately, decrease the cerebral metabolic oxygen rate, decrease the CBF, and decrease the ICP (Hussein et al., 2022; Munari et al., 2022). The outcome of this patient was good; on the GlasgowComa Scale 15, hemodynamics was stable, there was no seizure, and the patient could be transferred to the room.

The strength of this case report is that it is a rare case in our hospital and full of challenges for the neurosurgeon and neuroanesthesia. Neuroanesthesia management is complex, so we need knowledge, skills, and medical equipment for procedure and monitoring. The limitation of this case report was that the patient was in a high-risk procedure, but the facilities were provided, not advanced hemodynamic monitoring. The skills of neurosurgeons also are the key to the successful removal of tumor procedures when bleeding control. The excellent management of neuro anesthesia will support the success of maintaining stable hemodynamics and better outcomes.

#### 4. CONCLUSION

It is very unusual to see giant meningiomas like our case. The optimal conditions for meningioma tumor surgery are challenging for anesthetists to minimize edema and bleeding. A wide variety of medications are available for general anesthesia management. Therefore, the anesthetist must know the effects of each drug used to maintain the patient's hemodynamic condition and achieve a flaccid state of the brain tissue.

#### References

- 1) Aitkenhead, A. R., Smith, G., & Rowbotham, D. J. (2007). Textbook of anaesthesia. Elsevier Health Sciences.
- 2) Andrzejowski, J., & Fraser, J. (2010). Cottrell and Young's Neuroanaesthesia. Oxford University Press.
- 3) Eissa, M. F., Zaki, R. A. E. H., & El Noty, N. Z. (2020). Management of parasagittal meningiomas invading superior sagittal sinus. The Scientific Journal of Al-Azhar Medical Faculty, Girls, 4(2), 166–173.
- 4) Hafez, M. M. E., Bary, T. H. A., Ismail, A. S., & Mohammed, M. A. M. (2015). Frontolateral key hole craniotomy approach to anterior cranial base. Zagazig University Medical Journal, 19(1).
- 5) Hussein, Z., Zakaria, W. A. W., & Luoma, A. M. V. (2022). Anaesthesia for neurosurgery. Anaesthesia & Intensive Care Medicine, 23(12), 782–787.
- 6) Jf, B. (2013). Morgan & Mikhail's clinical anesthesiology. Mcgraw Hill.



- 7) Munari, M., De Cassai, A., Sandei, L., Correale, C., Calandra, S., Iori, D., Geraldini, F., Vitalba, A., Grandis, M., & Chioffi, F. (2022). Optimizing post anesthesia care unit admission after elective craniotomy for brain tumors: a cohort study. *Acta Neurochirurgica*, 1–7.
- 8) Narayan, V., Bir, S. C., Mohammed, N., Savardekar, A. R., Patra, D. P., & Nanda, A. (2018). Surgical management of giant intracranial meningioma: operative nuances, challenges, and outcome. *World Neurosurgery*, 110, e32–e41.
- 9) Nguyen, A., Mandavalli, A., Diaz, M. J., Root, K. T., Patel, A., Casauay, J., Perisetla, P., & Lucke-Wold, B. (2023). Neurosurgical anesthesia: optimizing outcomes with agent selection. *Biomedicines*, 11(2), 372.
- 10) Ogasawara, C., Philbrick, B. D., & Adamson, D. C. (2021). Meningioma: a review of epidemiology, pathology, diagnosis, treatment, and future directions. *Biomedicines*, 9(3), 319.
- 11) Pasternak, J. J. (2022). An Update on Neuroanesthesiology Update. *Journal of Neurosurgical Anesthesiology*, 34(1), 1–2.
- 12) Rehatta, N. M., Hanindito, E., & Tantri, A. R. (2019). *Anesthesiologi dan Terapi Intensif: Buku Teks Kati-Perdatin*. Gramedia pustaka utama.
- 13) Richard, S. A., Zheng, S., Xuehua, X., Bowen, C., & You, C. (2019). A giant invasive parasagittal meningioma with recurrent seizures in a young female: a case report and review of literature. *Interdisciplinary Neurosurgery*, 15, 41–46.
- 14) Rock, A. K., Opalak, C. F., Workman, K. G., & Broaddus, W. C. (2018). Safety outcomes following spine and cranial neurosurgery: evidence from the National Surgical Quality Improvement Program. *Journal of Neurosurgical Anesthesiology*, 30(4), 328–336.
- 15) Sanai, N., Sughrue, M. E., Shangari, G., Chung, K., Berger, M. S., & McDermott, M. W. (2010). Risk profile associated with convexity meningioma resection in the modern neurosurgical era. *Journal of Neurosurgery*, 112(5), 913–919.
- 16) Zhang, W., Neal, J., Lin, L., Dai, F., Hersey, D. P., McDonagh, D. L., Su, F., & Meng, L. (2019). Mannitol in critical care and surgery over 50+ years: a systematic review of randomized controlled trials and complications with meta-analysis. *Journal of Neurosurgical Anesthesiology*, 31(3), 273–284.