

SCHWANNOMAS OF UNUSUAL SITES – A CASE SERIES REPORT

**Dr. SK. Roshakhi Sultana¹, Dr. N. J. Abinешwar², Dr. C. Rajasekaran³,
Dr. Abhiram Kanth J R^{4*}, Dr. J Sridhar⁵ and Dr. B Nikhil Reddy⁶**

^{1,4,6} Postgraduate, Department of General Surgery, Vinayaka Mission's Kirupananda Variyar Medical College, Vinayaka Mission's Research Foundation (DU), Salem, Tamil Nadu, India.

Email: ¹roshakhi.shaik@gmail.com, ⁴abhiram.kanth490@gmail.com (*Corresponding Author),
⁶nikhilreddy7771@gmail.com

ORCID ID: ¹0009-0005-8752-8063, ⁴0009-0006-6301-3417, ⁶0009-0008-1795-3875

² Assistant Professor, Department of General Surgery, Vinayaka Mission's Kirupananda Variyar Medical College, Vinayaka Mission's Research Foundation (DU), Salem, Tamil Nadu, India.

Email: abinешwar@gmail.com

³ Professor and Unit Chief, Department of General Surgery, Vinayaka Mission's Kirupananda Variyar Medical College, Vinayaka Mission's Research Foundation (DU), Salem, Tamil Nadu, India.

Email: drcraja@gmail.com

⁵ Professor & Head, Department of General Surgery, Vinayaka Mission's Kirupananda Variyar Medical College, Vinayaka Mission's Research Foundation (DU), Salem, Tamil Nadu, India.

Email: drsridhar2002@yahoo.com

DOI: [10.5281/zenodo.11102425](https://doi.org/10.5281/zenodo.11102425)

Abstract

Schwannomas otherwise called as neurilemmomas, which are usually benign peripheral nerve sheath tumours which arise from Schwann cells that surround the nerve. It is usually benign, well encapsulated tumour, which forms a single, round, or fusiform mass with firm consistency on the course of a nerve. They are usually white to grey in colour. The mentioned cases were followed from April 2022 to December 2023 operated in Vinayaka Mission's Kirupananda Variyar medical college and hospital, Salem. All the patients presented to the opd with a complaint of swelling over the respective region and appropriate investigations have been done to prove it as a schwannoma. Here, we have talked about a series of cases with uncommon locations for ancient schwannoma, three cases involving the upper limb, involving the lower limb five cases and two cases in other regions (chest wall, behind the ear). With no significant problems, full excision was done to treat all patients. The benign tumours were completely removed while preserving the involved nerve in some cases and sacrificing it in some cases. Two cases have shown post-operative temporary anaesthesia over the surgical site which was resolved in 6 weeks in one case and 8 weeks in another case. Post-operative neuropraxia was complained in one case, which resolved in 6 weeks. The excision of the tumour was challenging because of its proximity to the nerve involved. Hence care was taken to preserve the nerve as much as possible. Hpe: post-excision histopathology in all cases showed signs of hypocellular and hypercellular areas with spindle cells, with Antoni-a and Antoni-b areas and elongated wavy nuclei with dense chromatin with verocay bodies. Ancient schwannoma.

Keywords: Schwannoma, Benign, Spindle Cells, Verocay Bodies, Neuropraxia.

INTRODUCTION

Schwannomas otherwise called as neurilemmomas, are benign peripheral nerve sheath tumours which arise from Schwann cells that surround the nerve. It is one of the few truly encapsulated neoplasms and is usually solitary. Most common nerve involved is vestibulocochlear nerve referred as *vestibular schwannoma* (also known as an acoustic neuroma). Peripheral schwannomas are rare, usually 1-5 %. An unusual subtype of schwannoma that is rare, encapsulated and of long duration is called an ancient schwannoma. Schwannomas usually have rare possibility of changing into malignancy and present usually as benign variants.

They can be seen as one of the components of type 2 Recklinghausen disease where it is seen in groups.

Genetically schwannomas are characterized by somatic mutation in sporadic form or germline mutations of nf2 gene in 1 allele and loss of nf2 in the other allele through monosomy or deletion in neurofibromatosis type 2.

They are usually slow growing, painless swellings without any hinderance to daily activities. Therefore, at the time of the presentation swellings are significantly large and usually present only when the swelling gives rise to symptoms like pain or paraesthesia. In case of larger swellings confined in tight fascial compartments have chances of motor deficit.

Usually, the nerve from which the schwannoma arises is seen in the peripheral and flattened along the nerve capsule, but do not penetrate substance of the tumour.

As it is seen as a benign entity all the time, care should be taken to preserve the nerve. There is a higher chance of iatrogenic nerve damage due to its close association with the involved nerve. In some cases, there can be permanent nerve damage leading to adverse end results. Therefore, careful resection of the tumour and preserving the nerve is utmost important.

All the below discussed patients came with the common complaints of mass in the respective regions. A few patients have complained of associated pain. All the patients were evaluated preoperatively both clinically and with radiological investigations. In a few cases mri was done to look for the proximity of the nerve to the swelling.

Histopathological examination turned out as schwannomas in all cases. All the cases were followed for maximum period of 18 months and minimum period of at least 6 months.

Case series:

Case 1:

A 60-year female came with complaints of swelling in the popliteal region for 6 months and associated with pain. On examination an ovoid mass of 3x2 cms was noted in popliteal fossa, which was smooth surfaced, non-pulsatile, firm in consistency, and not fixed to skin. Excision was done under spinal anaesthesia (Fig-1).

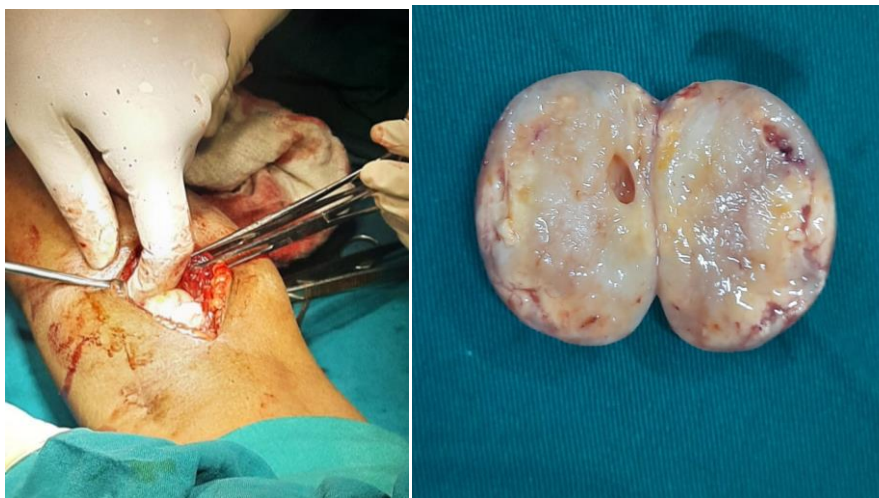


Figure1: Swelling in the popliteal region

Case 2:

This case is a 11-year-old male child presented to OPD with a swelling behind the right ear for the past 2 years. Patient gives a history of pain since the last 15 days with no history of any discharge, referred pain to ear or headache(Fig-2).

On clinical examination, approximately 2x2 cms ovoid mass was noted behind right ear, which was non-tender on palpation. The mass was smooth surface and firm in consistency and found to be not fixing to the underlying bone or overlying skin. Lump excised under local anaesthesia.

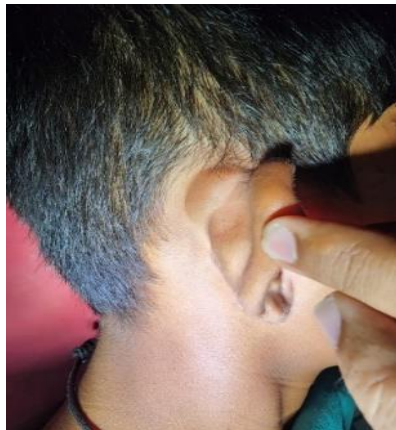

Figure 2:swelling behind the right ear

Postoperatively patient has complained of neuropraxia which spontaneously resolved in 6 weeks.

Case 3 :

56 yrs male presented with swelling over the anterior aspect of thigh for the past 6 years which was gradually increased size. Investigations were done and removed under spinal anaesthesia(Fig-3).

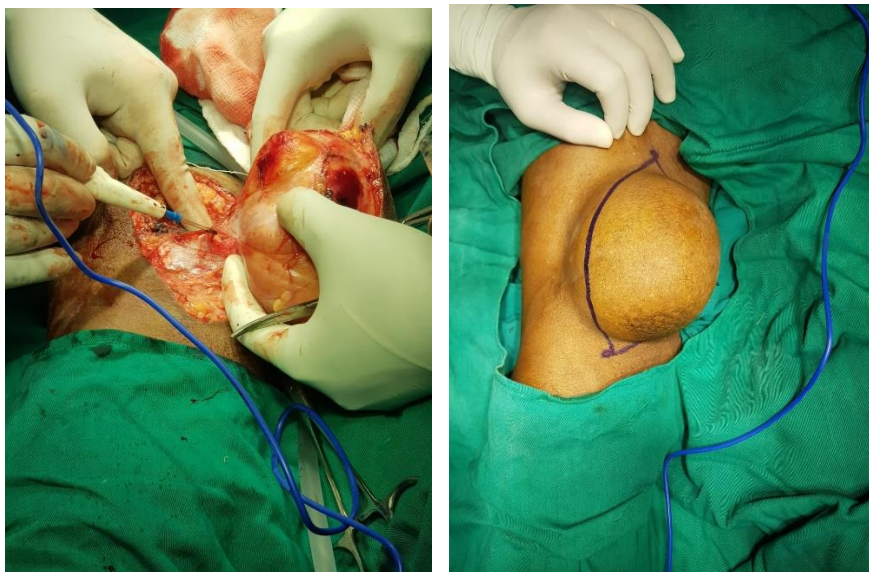


Figure 3: Swelling over the anterior aspect of thigh

Case 4 :

This case was a 65 year old male presented with long standing, dull aching, diffuse abdominal pain. Patient was evaluated and diagnosed as retroperitoneal liposarcoma preoperatively. Excision was done under general anesthesia. On histopathological examination schwannoma was discovered in a few slides(Fig-4).

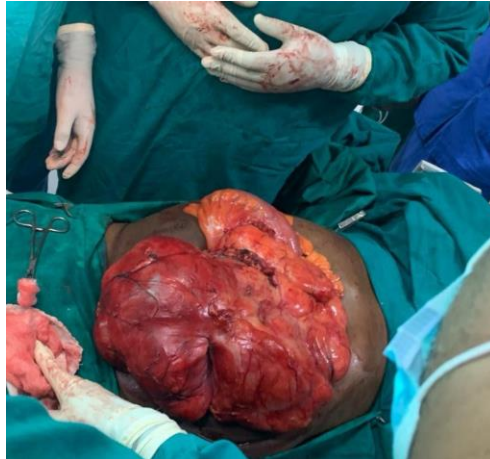

Figure 4: Retroperitoneal liposarcoma

Case 5:

This is a 42 year male came with multiple swellings all over the body. Patient came with complaints of pain over the large swelling present over the left upper-arm(Fig-5).

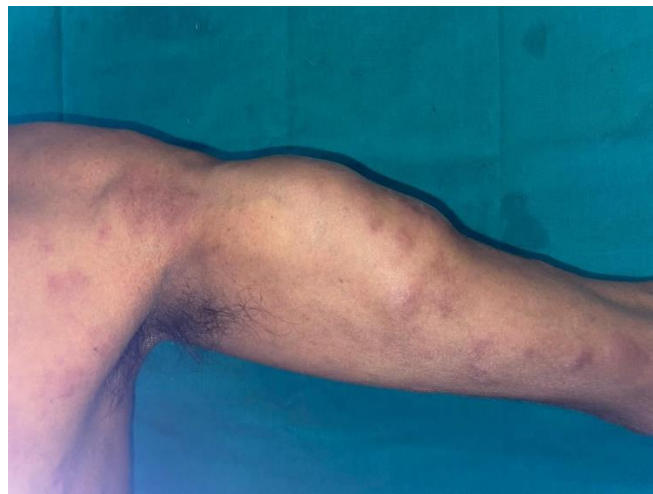


Figure 5: Swelling present over the left upper-arm

Patient was diagnosed with neurofibromatosis and this particular swelling was removed under general anesthesia and was diagnosed as schwannoma on histopathological examination.

Case 6:

32 years male presented with the complaints of swelling over lateral aspect of the right thigh for the past 6 years. The swelling was painless initially. Complaints of pain over the swelling radiating to the right lower limb were present for the past 15 days. Excision was done under spinal anesthesia(Fig-6).

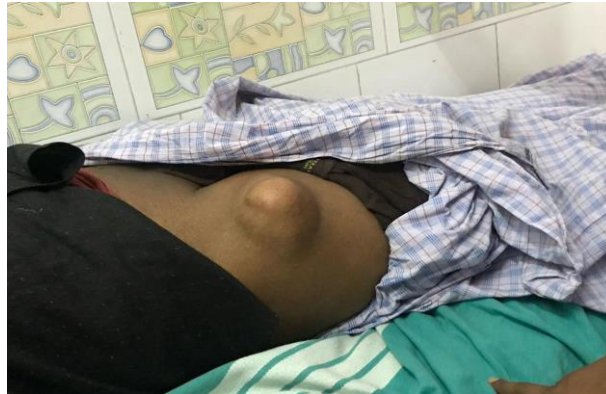

Figure 6: of Swelling over lateral aspect of the right thigh

Case 7:

A 52 year female presented with swelling over the left shoulder for 6 months which was painless. Excision was done under local anesthesia(Fig 7).

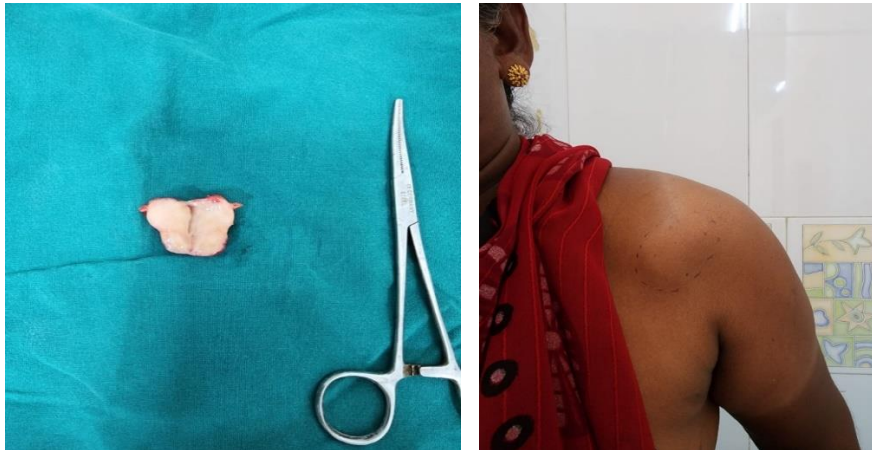

Figure 7 : Swelling over the left shoulder

Case 8:

41-year male came with the complaints of painless swelling on the anterior aspect of the right thigh for past 15 years. Excision was done under spinal anaesthesia(Fig-8).

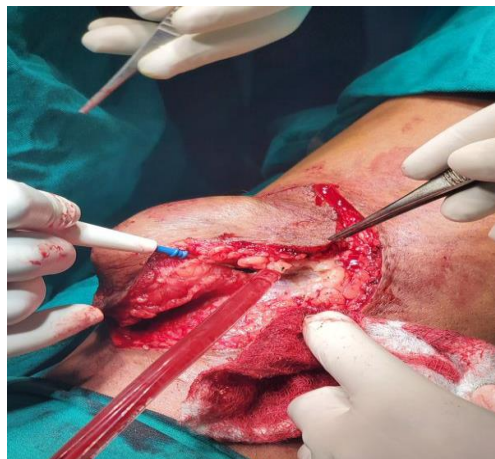

Figure 8: Swelling on the anterior aspect of the right thigh

Local skin flap was raised in this case to cover the deficit skin.

Patient complained of paraesthesia around the operated area which was settle in 8 weeks partially and completely by 9 months.

Case 9:

This case was a 22-year-old who was undergoing complete medical examination for the purpose of armed forces examination and was found to have a swelling over the anterior chest wall over the right side. Patient had no complaints and was operated for his examination(Fig-9).

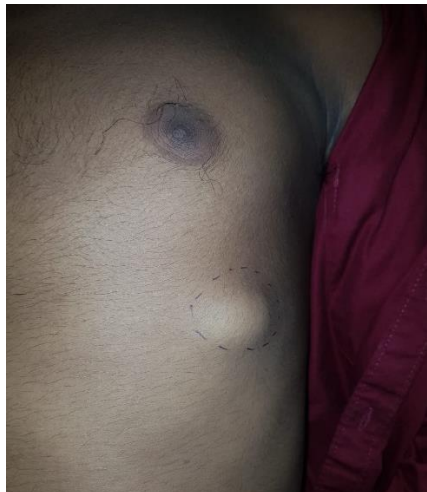

Figure 9: Swelling over the anterior chest wall

Case 10:

A 39-year old male came with complaints of swelling over the nape involving the occipital region about a size of 15x15 cms. Initially it was diagnosed as lipoma clinically and histopathological examination revealed schwannoma surrounded by lipomatous tissue(Fig-10).

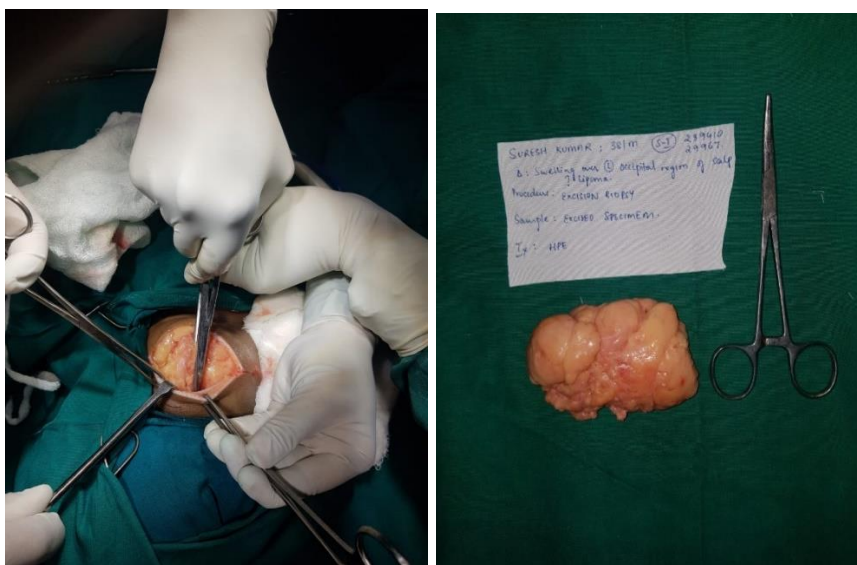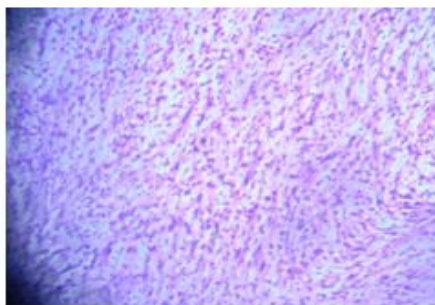


Figure 10: Swelling over the nape involving the occipital region

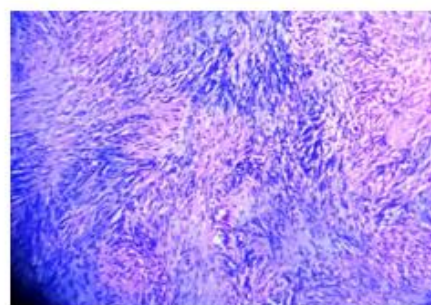
HISTOPATHOLOGY:

All the above cases have shown the characteristic histological features include as below.

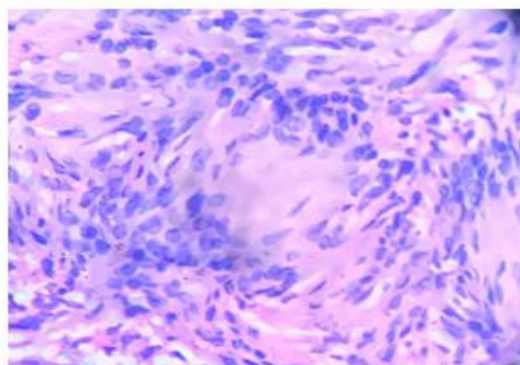
- The presence of Antoni A and Antoni B areas in alternating fashion.
- A region is made up of interlocking fascicles of spindle-shaped Schwann cells, or HYPOCELLULAR AREAS in nuclear palisading fashion.
- Eosinophilic Verocay bodies are formed by the cell processes in between two compact rows of well-aligned nuclei.
- The loose meshwork of microcystic and gelatinous tissue makes up the Antoni B region.



ANTONI-A AREAS



ANTONI-B AREAS



VEROCAY BODIES

DISCUSSION

Schwannomas which are also called as neurilemmomas are usually benign, solitary nerve sheath tumours which are usually solitary. They account for 1-5 % of all the soft tissue tumours ^[1]. These are very rare tumours and is usually misdiagnosed as commonly existing non-benign tumours like lipoma, fibroma, or ganglions etc, due to lack of awareness in the patients. The tumours of peripheral nerve sheath have different variations of malignant potential which can be from neurofibroma or benign schwannomas or high-grade peripheral nerve sheath tumours. The benign structures may be isolated schwannomas or neurofibromas, which are linked to Von Recklinghausen disease^[2-4]. These are well circumscribed usually encapsulated involving the proximal nerves^[3-5]. Neurofibromas usually develop within the nerve

which cause fusiform dilatation where schwannomas displace the nerve leading to the symptoms^[6]. Although malignant transformation of schwannomas is uncommon, a review by Ziadi suggested that schwannomas may have been the source of 10 out of 32 instances. Malignant nerve sheath tumors (MNST) of the cranial nerves were present in each of the ten cases. Thus, he proposed the theory that cerebral MNSTs, as opposed to their peripheral counterpart, may be more closely linked to schwannoma^[7].

Schwannomas can occur in any of the part of the body and any of the peripheral nerves. In the cases we have studied most of the occurrences were in upper and lower limbs. Schwannoma is typically located on the anterior aspect of the upper limb and the posterior aspect of the lower limb, according to Stull MA et al.^[8]. In this study mixed cases were seen. Schwannomas have a variable size varying from 2cm to 20 cms^[9]. In our study the largest was about 15 cms x 15 cms. The usual age is between 20-50 years^[10]. In our study it varied from 11 to 68 years.

Most of the patients ignored the tumours due to painlessness and consulted only when the swelling became significantly large producing pain or compressing the nerves causing paraesthesia. Patients may have an initial differential diagnosis as fibroma, Xanthomas or lipomas making the actual diagnosis difficult preoperatively^[11]. A diagnosis made solely based on a clinical evaluation can occasionally be challenging and deceptive. Only 31% of upper extremity schwannoma cases were correctly diagnosed by Phalen^[12].

They may be deeply seated in the intramuscular or intermuscular plane, or they may be superficial and readily accessible, depending on the origin of the nerve. The incision should be positioned so that it extends over the portion of the nerve that is not affected by the tumor and rests directly over it. Care should be taken to preserve the nerve. As schwannomas are very well encapsulated tumours there is a minimal chance of infiltration into the adjacent nerve tissue giving it little chance to leave the tumour tissue behind leading to recurrences and malignant transformation into cancerous soft tissue sarcoma or malignant nerve sheath tumour later in life (incidence less than 5%). Postoperatively 2 patients have complained of neuropraxia which was settled completely by 9 months.

CONCLUSION

Neurilemmomas, another name for Schwannomas, are benign tumors that grow outside of the peripheral nerve sheath and can originate from any nerve in the body. They typically don't truly involve the involved nerve, but they are physically close to it. They can be preoperatively diagnosed with the help of MRI. With proper care and good surgical techniques complete tumour enucleation can be done without any nerve damage or recurrences.

Disclosure: no conflicts of interest.

Ethical statement:

Institutional ethical committee accepted and approved this study. Ethical approval for the study was given by the Vinayaka Mission's Kirupananda Variyar Medical College and Hospital, Salem, Institutional Ethical Committee. Written consent was obtained from study participants prior to the study. The confidentiality of the study participants was maintained. Informed written consent was obtained from the study participants.

Funding: Nil.

Data Availability:

All datasets generated or analysed during this study are included in the manuscript.

Informed Consent:

Written informed consent was obtained from the participants before enrolling in the study

References

- 1) Kransdorf MJ. Benign soft-tissue tumors in a large referral population: distribution of specific diagnosis by age, sex, and location. *AJR Am J Roentgenol* 1995;164:395-402.
- 2) Lin J, Martel W. Cross-sectional imaging of peripheral nerve sheath tumors: characteristic signs on CT, MR imaging, and sonography. *AJR Am J Roentgenol*. 2001;176:75-82.
- 3) Lee JA, Boles CA. Peripheral schwannoma lacking enhancement on MRI. *AJR Am J Roentgenol*. 2004;182:534-35.
- 4) Maraziotis T, Panagiotopoulos E, Panagiotopoulos V, Panagiotopoulos K, et al. Neurilemoma of the popliteal fossa: report of two cases with long subclinical course and misleading presentation. *Acta Orthop Belg*. 2005;71(4):496-99.
- 5) Ozdemir O, Ozsoy MH, Kurt C, Coskunol E, Calli I. Schwannomas of the hand and wrist: long-term results and review of the literature. *J Orthop Surg*. 2005;13:267-72.
- 6) Pino C, Ghazle H, Bhatt S, Dogra V. Schwannoma of tibial nerve. *Journal of Diagnostic Medical Sonography*. 2010;26(4):205-08.
- 7) Ziadi A, Saliba I. Malignant peripheral nerve sheath tumours of intracranial nerves: A cases series review. *Auris Nasus Larynx*. 2010;37(5):539-45.
- 8) Stull MA, Moser RP, Kransdorf MJ, Bogumill GP, Nelson MC. Magnetic resonance appearance of peripheral nerve sheath tumors. *Skeletal Radiol*. 1991;20:9-14.
- 9) Maleux G, Byrs P, Samson I, Sciot R, Baert AL. Giant schwannoma of the lower leg. *Eur Radiol*. 1997;7:1031-34. [10] Schreuder HWB, Veth RPH, Lemmens JAM, Larhooven EW. Intraosseous.
- 10) Kang HJ, Shin SJ, Kang ES. Schwannomas of the upper extremity. *J Hand Surg Br*. 2000;25:604-07.
- 11) Phalen GS. Neurilemomas of the forearm and hand. *Clin Orthop Relat Res*. 1976;114:219-22.