

LATERAL SACCULAR CYST OF LARYNX – A RARE CASE REPORT

Dr. Alekhya Vemula ¹, Dr. Deepak Raj ² and Dr. Shyam Sudhakar ^{3*}

¹ Final Year Postgraduate, Department of ENT, Saveetha Medical College and Hospital, Saveetha Institute of Medical and Technical Sciences (SIMATS), Chennai, India.

² Senior Resident, Department of ENT, Saveetha Medical College and Hospital, Saveetha Institute of Medical and Technical Sciences (SIMATS), Chennai, India.

³ Associate Professor, Department of ENT, Saveetha Medical College and Hospital, Saveetha Institute of Medical and Technical Sciences (SIMATS), Chennai, India.

(*Corresponding Author)

DOI: 10.5281/zenodo.11195430

Abstract

Introduction: Laryngeal cysts comprise approximately 5-10% of noncancerous laryngeal abnormalities. Lateral saccular cysts are rare and pose a diagnostic challenge and appropriate selection of treatment modality is essential for improving patient outcomes and decreasing hospital stays. This case report describes successful management of saccular cysts via endoscope guided direct laryngoscopy and excision via a transoral approach. **Case report:** A 54year-old male patient reported hoarseness of voice, persistent foreign body sensation in the throat and dysphagia for the past 2 months. Video laryngoscopy, Ultrasonography and neck contrast enhanced CT revealed two synchronous existing laryngeal cysts that did not communicate with each other. The patient was then successfully managed by excision of the cyst via endoscope guided direct laryngoscopy via a transoral approach which improved patient outcomes and had no recurrence. **Conclusion:** Laryngeal cysts, although rare, are clinically important because they present diagnostic challenges and may pose life-threatening risks, such as breathing difficulties resulting from airway obstruction. The external approach might be limited to treating large recurrent cysts. Small lateral saccular cysts can be managed successfully by endoscope-assisted laryngeal microsurgery through a transoral approach without any recurrence.

INTRODUCTION

Laryngeal cysts can develop in any area of the larynx lined with mucosa, comprising approximately 5% to 10% of noncancerous laryngeal abnormalities. [8] Various types of laryngeal cysts include ductal cysts, saccular cysts, and cysts within the thyroid cartilage foramen. Saccular cysts alone constitute 25% of all laryngeal cysts[10]

Saccular cysts, located beneath the false vocal cords, aryepiglottic folds, and anterior ventricle, are believed to originate from the sacculus laryngis undergoing cystic distention. [3] Anatomically, a significant saccule is defined as extending superiorly beyond the thyroid cartilage to the level of the thyrohyoid membrane. If the saccule remains beneath the membrane, it is termed internal, while if it protrudes (usually where the superior laryngeal bundle penetrates the membrane), the superficial portion is termed external. [8]

Initial treatment for anterior saccular cysts may involve endoscopic excision. [7] Achieving a precise diagnosis and selecting an appropriate treatment strategy are crucial to reduce treatment-related complications and recurrence. The endoscopic approach facilitates a thorough magnified examination of the saccular cyst, offering advantages as a minimally invasive method compared to the open approach and promoting swift patient recovery. [1]

This case report highlights the clinical presentation of a saccular laryngeal cyst and its successful management through transoral excision of the cyst via endoscopic-assisted direct laryngoscopy.

Case Report:

A 54-year-old male patient presented to our outpatient department (OPD) with a primary complaint of hoarseness of voice for the past two months. He had a history of persistent foreign body sensation in his throat, with instances of aspiration and coughing while consuming liquids for more than 2 months. Hoarseness and persistent foreign body sensation in the throat were not associated with any aggravating or relieving factors. The patient also had difficulty swallowing, breathlessness, weight loss, and loss of appetite. Routine clinical examination, including ear, nose, throat examination revealed normal findings, and the patient's vital signs were stable.

Neck examination revealed swelling measuring 1x1 cm on the left side, located superior to the thyroid gland. The swelling was non compressible, was immobile, did not expand on cough, and showed firm to cystic consistency, and the skin covering it appeared normal with no associated pain or tenderness.

Video laryngoscopy revealed left vallecular fullness, extending and obliterating the left pyriform sinus, and epiglottis displaced to the right. The left false cord, bilateral arytenoids and interarytenoid region showed minimal oedema and medial displacement of the left aryepiglottic fold. Both true vocal cords are mobile. Saliva aspiration was observed. The glottic chink appeared adequate.

Ultrasonography (USG) of the neck revealed a 1x1 cm anechoic lesion on the left side, likely a laryngeal cyst. Contrast enhanced CT neck imaging revealed a 3.6x3.6x1.8 cm cyst internal to the thyroid cartilage arising from below the left false vocal cord with thyroid cartilage erosion extending into left thyrohyoid muscle.(Figure 2A), and a small cyst external to the thyroid cartilage above the thyroid gland on the left side did not communicate with the internal cyst (Figure 2B).

Preoperatively, the patient received intravenous antibiotics and anti-inflammatory medications. After anaesthesia clearance was achieved, the patient underwent complete excision of the cyst via transoral endoscope-assisted direct laryngoscopy. The cyst was seen extending along the laryngeal surface of the epiglottis. The cyst was completely excised and sent for histopathological examination (HPE) and only a small amount of the cyst wall was left intact at the petiole of the epiglottis. A midline horizontal neck incision was made with 2 finger breadths above the suprasternal notch, the subcutaneous skin tissue was dissected, the sub platysmal flap was elevated, and the strap muscles were retracted. The cysts on the left side, superior to the thyroid gland, were dissected and excised in total and sent for HPE and fluid analysis.

The fluid analysis was negative for malignant cells. The smears revealed sheets of cyst macrophages, along with scattered inflammatory cells and occasional clusters of round to oval epithelial cells against an eosinophilic background.

Histopathological examination (HPE) revealed that the cyst wall was lined by stratified squamous epithelium, exhibiting oedema, congested blood vessels, and haemorrhage. No atypia or malignancy was observed, consistent with the features indicative of a benign laryngeal cyst. (As shown in Figure 3)

Following the operation, the patient was instructed to observe complete voice rest for one week and received treatment with intravenous antibiotics, analgesics, and anti-inflammatory medications. Additionally, intravenous steroids and steroid nebulisation were administered for three days postoperatively.

Repeat video laryngoscopy on postoperative day 2 revealed postoperative alterations on the lingual surface of the epiglottis. Fullness over the vallecula decreased, along with a reduction in prominence of the aryepiglottic folds. Aspiration was not observed. Both the bilateral true and false vocal cords exhibited normal anatomy and function.

The patient improved symptomatically in terms of breathlessness, pain, difficulty swallowing, and voice hoarseness and was discharged on POD 3 with a course of oral antibiotics and oral steroids.

The patient was followed up for 4 weeks after surgery and had no signs of recurrence.

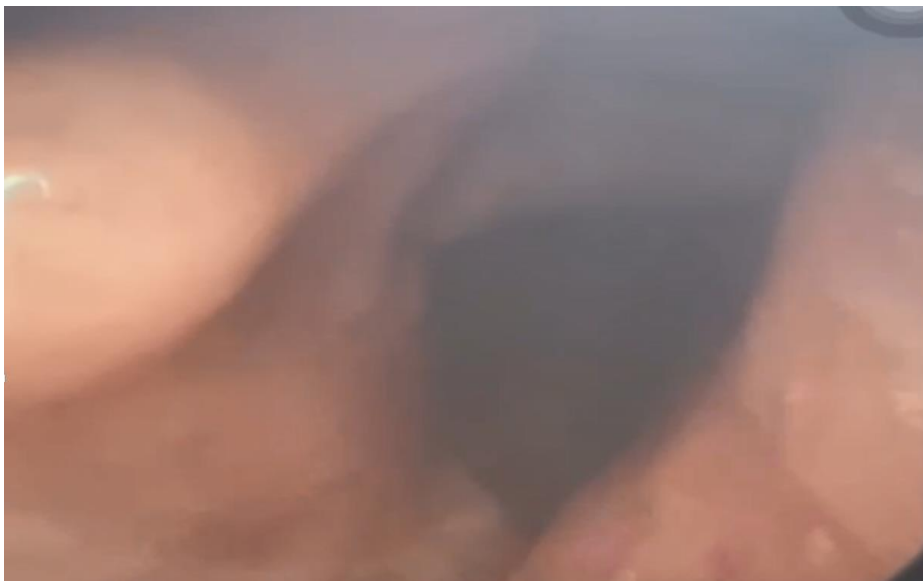

Figure 1

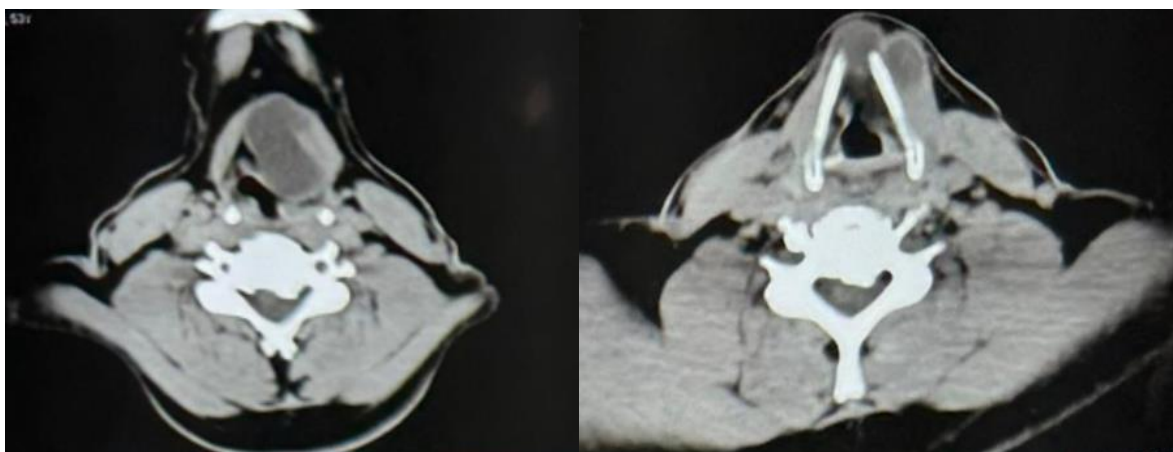


Figure 2A

Figure 2B

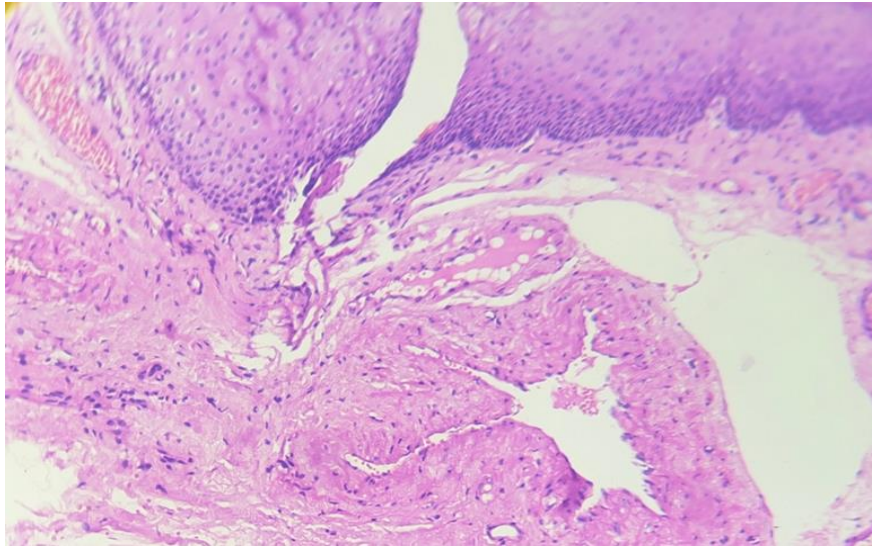


Figure 3

DISCUSSION

The saccule is a membranous sac in the larynx situated between the false and true vocal cords and the inner surface of the thyroid cartilage and has mucous-secreting glands that lubricate the vocal cords. Blockage of its orifice or gland ducts can lead to cyst formation, which often occurs in older individuals. They may present congenitally or may eventually develop due to degenerative causes [10].

Laryngeal cysts can be categorised into ductal and saccular types. Ductal cysts, the most common cysts, typically form where mucosal glands are present in the laryngopharynx, excluding the gland-free region on the true vocal cords. They arise from mucus buildup in gland ducts, are usually small in size (less than 1 cm), and are lined with double-layered epithelium composed of inner columnar and outer cuboidal cells. Saccular cysts are less common supraglottic lesions, they are dilated sacs not connected to the laryngeal lumen and are usually larger than ductal cysts (rarely smaller than 1 cm). They have a stratified squamous epithelium with varying lymphocyte presence in their walls. Saccular cysts, though rare, pose risks of airway obstruction and may undergo malignant transformation, as they are usually associated with squamous cell carcinoma [1,6]. Accurate diagnosis and appropriate treatment are vital for reducing morbidity and preventing recurrence.

Newman et al. (1984) introduced a revised classification for laryngeal cysts, categorising them into various types. These include epithelial cysts, with or without lymphoid tissue, characterised by either columnar or squamous epithelial lining. Tonsillar cysts resemble tonsillar crypts, with a squamous epithelial lining and underlying follicular lymphoid tissue. Additionally, there are oncocytic cysts lined by oxyphilic/oncocytic epithelium. Histological analysis aids in comprehending the behaviour and origin of different laryngeal cysts. This classification system recognises the impact of lymphoid tissue on cyst pathogenesis. This finding also underscores the importance of oncocytic cysts, a unique histological type prone to recurrence that is indicative of a widespread metaplastic process [5].

Saccular cysts can be categorised as anterior or lateral. An anterior-type cyst expands between the true and false vocal cords, growing medially and posteriorly. A lateral-type cyst extends in a posterosuperior direction between the false vocal cords and the aryepiglottic folds[1]

Depending on its size, this cyst can distort the aryepiglottic fold, false cord, or ventricle either individually or in combination. These structures are displaced and distorted as they are pushed into the laryngeal lumen. Larger cysts may protrude laterally into the pyriform sinus and superiorly to raise the floor of the vallecula. They often extend over the true cords, partially obscuring the glottis and leading to airway obstruction and breathing difficulties. It can also extend into the neck through the foramen of the superior laryngeal bundle in the thyrohyoid membrane, reaching the upper portion of the anterior cervical triangle, known as an external cyst. [3]

Symptoms differ based on age, cyst size, and whether the cyst extends into the neck. Infants with laryngeal saccular cysts typically show signs of stridor, weak crying, and/or feeding issues[11]. In adults, symptoms resemble those of any laryngeal space-occupying lesion, such as tumors, laryngoceles, or other cysts. Common signs include hoarseness or voice weakness, with variable symptoms of dyspnoea and difficulty breathing. Dysphagia occasionally occurs as well[3]. Incomplete adduction of the vocal folds, caused by a cystic mass in the laryngeal ventricle, can lead to aspiration[1].

Treatment for saccular laryngeal cysts varies. In infants, initial treatment typically involves needle aspiration. For adults, therapy often includes endoscopic needle aspiration, endoscopic marsupialization of the cyst with local excision under direct laryngoscopy, and endoscopic extended ventriculotomy. [6,11] Compared with open surgery, the endoscopic method allows for a close examination of the saccular cyst, offering advantages of minimally invasive treatment and quicker patient recovery. CT scans are crucial for diagnosing lateral saccular cysts, distinguishing them from laryngoceles. [1,2]

The selection of definitive surgical treatment is contentious due to the rarity of the condition. Few case series are available in the literature. Endoscopic radiofrequency ablation is suggested as a relatively safe and effective method for removing recurrent saccular cysts, offering improved surgical precision, minimal bleeding, and enhanced healing. [11] Management of saccular cysts involves securing the airway and removing the lesion. Successful results can often be attained through endotracheal intubation followed by cyst marsupialization. [12] Growing evidence suggests that a transoral approach could be used to effectively manage even the most intricate cysts. [8]

This case report illustrates the presence of two synchronous non communicating laryngeal cysts and their successful treatment through complete cyst excision via a transoral approach.

CONCLUSION

Laryngeal cysts, although rare have significant clinical importance because they present diagnostic challenges and may pose life-threatening risks, such as breathing difficulties resulting from airway obstruction. Selecting the appropriate treatment is crucial for addressing these concerns, preventing recurrence, and minimising postoperative burdens such as the need for tracheostomy and prolonged hospitalisation for the patient. The external approach might be limited for treating large recurrent cysts, as increasing evidence indicates that a transoral approach can

successfully treat even the most complex cysts. Two synergistic laryngeal cysts can simultaneously exist without any communication between them. Small lateral saccular cysts can be managed successfully by endoscope-assisted laryngeal microsurgery through a transoral approach without any recurrence. Complete excision of the cyst along the laryngeal surface is necessary, as marsupialization alone results in a cyst wall remnant that may cause persistent foreign body sensation, breathing difficulty and airway obstruction postoperatively.

References

- 1) Kim JH, Kim MH, Ahn HG, Choi HS, Byeon HK. Clinical Characteristics and Management of Saccular Cysts: A Single Institute Experience. *Clinical and Experimental Otorhinolaryngology*. 2019 May 1;12(2):212–6.
- 2) M. Hossam Thabet, Hesham Kotob. Lateral saccular cysts of the larynx. Aetiology, diagnosis and management. *The Journal of Laryngology & Otology*. 2001 Apr 1;115(04).
- 3) DeSanto LW, Devine KD, Weiland LH. Cysts Of The Larynx?? Classification. *The Laryngoscope*. 1970 Jan 1;80(1):145–76.
- 4) Ramesar K, Albizzati C. Laryngeal cysts: clinical relevance of a modified working classification. *The Journal of Laryngology & Otology*. 1988 Oct 1;102(10):923–5.
- 5) Newman Bh, Taxy Jb, Hi L. Laryngeal Cysts in Adults: A Clinicopathologic Study of 20 Cases. *American Journal of Clinical Pathology*. 1984 Jun 1;81(6):715–20.
- 6) Kinnunen I, Klemi P, Grenman R. Saccular Laryngeal Cysts. *ORL*. 2000;62(2):109–11.
- 7) SNIEZEK JC, JOHNSON RE, RAMIREZ SG, HAYES DK. Laryngoceles and Saccular Cysts. *Southern Medical Journal*. 1996 Apr;89(4):427–30.
- 8) Heyes R, Lott DG. Laryngeal Cysts in Adults: Simplifying Classification and Management. *Otolaryngology–Head and Neck Surgery*. 2017 Jul 1;157(6):928–39.
- 9) Kiell E. Endoscopic approach to congenital laryngeal cysts. *Operative Techniques in Otolaryngology-Head and Neck Surgery*. 2022 Sep 1;33(3):184–6.
- 10) Shaik FB, Kvs Kumar Chowdary. A Clinical Study of Laryngeal Cysts. *International journal of phonosurgery and laryngology*. 2016 Jan 1;6(2):53–6.
- 11) Kumar S, Garg S, Sahni JK. Radiofrequency ablation of laryngeal saccular cyst in infants: A series of six cases. *International Journal of Pediatric Otorhinolaryngology*. 2012 May 1;76(5):667–9.
- 12) Booth JB, Birck HG. Operative Treatment and Postoperative Management of Saccular Cyst and Laryngocele. *Archives of Otolaryngology-head & Neck Surgery*. 1981 Aug 1;107(8):500–2.