

CLINICO-DERMOSCOPIC EVALUATION OF NAIL PSORIASIS SEVERITY INDEX OF FINGERNAIL AND TOENAIL: A CROSS-SECTIONAL STUDY

Nikitha C ¹, Poongundran. C ^{2*},
Prathambigai S S ³ and Samyuktha Sendhil ⁴

^{1,2,3,4} Department of Dermatology, Venereology and Leprosy Saveetha Medical College Hospital, Saveetha Institute of Medical and Technical Sciences (SIMATS) Saveetha University.

*Corresponding Author Email: Poongundran95@gmail.com

DOI: [10.5281/zenodo.12077818](https://doi.org/10.5281/zenodo.12077818)

Abstract

Introduction: Nail changes can be seen in about 50% of the patients diagnosed with psoriasis. Dermoscopy is an in vivo, non-invasive method that aids in diagnosing nail disorders. **Aim:** To evaluate the Clinical and dermoscopic Nail Psoriasis Severity Index (NAPSI) score of toenail and fingernail. To correlate the Dermatological Life Quality Index (DLQI) score versus dermoscopic NAPSI of toe and fingernails. **Materials and Method:** A total of 90 patients were enrolled (male=58, female=32). Clinical and dermoscopic examination of affected finger and toenail nails was done. NAPSI and DLQI scores were documented. Pearson correlation coefficient test was used to compare NAPSI and DLQI score. Wilcoxon Sign Rank Test was performed to compare mean Dermoscopic NAPSI score between the toe and fingernail (p-value <0.05 was considered as statistically significant). **Results:** Pitting was the most common Nail matrix finding seen through (Dermoscope - 87.7% vs clinical- 83%). The most common nail bed finding was Subungual hyperkeratosis (Both clinical and dermoscope 63.3%). The mean dermoscopic NAPSI value of fingernail was higher than toenail (16.09 ± 6.86 vs 9.62 ± 4.91). **Conclusion:** The dermoscopic NAPSI score was higher than clinical NAPSI score. Nail psoriasis had a significant impact in the quality of life.

Keywords: Nail psoriasis, Pitting, Dermoscope, NAPSI, DLQI.

INTRODUCTION

Nail involvement is seen in 50% to 88% of psoriasis patients and even higher in patients with psoriatic arthritis. ^[1] The isolated involvement of nail changes without any skin involvement can occur in 5% of the patients. ^[2] Nail changes in psoriasis can have a psychological impact on the quality of life and can hinder their daily activities. ^[3] Dermatological life quality index (DLQI) can be used to assess the quality of life in patients with Nail psoriasis. ^[4] Nail biopsy is the gold standard in diagnosing psoriasis but proves to be diagnostic in only 50% of nail psoriasis. ^[5] Dermoscopy is an in vivo, non-invasive, and rapid method which aids in diagnosing pigmented skin and nail disorders. ^[6] An objective scoring system called the nail psoriasis severity index (NAPSI) was developed to observe the nail changes in psoriasis and evaluate the therapeutic efficacy of various treatment modalities. ^[7]

Aims and objectives:

- The aim of this study was to evaluate the various dermoscopic features in nail psoriasis
- To compare the NAPSI score of both toenail and fingernail through dermoscope and clinical observation.
- To assess the correlation between DLQI score and dermoscopic NAPSI score of toenail and finger nail.

MATERIALS AND METHODS

This observational-analytical study was conducted in the department of dermatology, Saveetha Medical College and Hospital, Thandalam, from June 2023 to January 2024. A total of 90 patients who were clinically diagnosed as psoriasis with nail involvement and who gave their consent for participation in the study were enrolled in this study.

Patients with Systemic disorders or concurrent other dermatological disorders like alopecia areata, lichen planus, onychomycosis, eczema that might influence the nail changes were excluded from the study. Nail clippings were collected to rule out fungal hyphae in patients with subungual hyperkeratosis to rule out onychomycosis.

All patients with nail features typical of psoriasis and patients with cutaneous features suggestive of psoriasis were included in the study. Nail bed and Nail biopsy was done wherever it was necessary.

DermliteDL4 dermoscope was used. Ultrasound gel was used to view various nail changes and photographs of the same were taken after informed consent. All 10 finger and toenails were first examined clinically and was followed by dermoscopic examination.

NAPSI score described by Rich et al ^[4] was used to calculate the nail severity scoring. It was calculated by dividing each nail into four quadrants.

Each quadrant was evaluated for the presence of any nail matrix findings (leukonychia, red lunula, nail plate crumbling and pitting) and nail bed findings (subungual hyperkeratosis, splinter haemorrhage, onycholysis and salmon patch).

A score of 1 was given for the presence any such finding in each quadrant, so that the nail matrix score was from 0-4, similarly a nail bed score of 0-4, thus the total score per nail ranging from 0-8 per nail.

NAPSI scores of Toe nails and Finger nails were calculated separately. Dermatology life and quality index (DLQI) described by Finlay et al ^[7] was calculated in the patients with appropriate questionnaire and the score ranged from 0-30.

STATISTICAL ANALYSIS

The statistical analysis was performed using SPSS software version 22. Frequencies were calculated for variables related to demographic, clinical and dermoscopic characteristics of patients. Continuous variables such as DLQI score, NAPSI score of affected fingernail and toenail, age, nail psoriasis duration are described as mean \pm standard deviations and ranges.

Categorical variables was presented as frequency and percentage. Pearson correlation coefficient test was performed to see the correlation between DLQI score vs dermoscopic NAPSI of finger and toenail.

Wilcoxon Sign Rank Test was performed to compare mean Dermoscopic NAPSI score between the toenail and fingernail. A p-value <0.05 was considered to be statistically significant.

RESULTS

A total of 90 patients were enrolled in this study out of which, 35.6% were female (N=32) and 64.4% were male (N= 58). The age of the study population ranged from 21 to 56 years (mean 36.98 ± 9.223). Isolated nail psoriasis was seen in 42.2% (N=38), 57.8% of patients had both cutaneous and nail psoriasis (N=52). Among these 52 people, cutaneous psoriasis was first seen in 57.7% (N=30) and 42.3% (N=22) of patients presented with Nail psoriasis developed cutaneous psoriasis later. The duration of cutaneous psoriasis ranged from 1 to 10 years (mean 4.22 ± 2.02) and the duration of Nail Psoriasis ranged from 1 to 6 years (mean 2.79 ± 1.410).

Pitting was the most common Nail matrix finding seen through Dermoscope and was found in 87.7% of the study population and clinically it was seen in 83.4% of the patients (FIGURE 1&2).

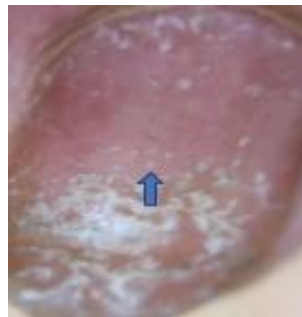


Figure 1: Arrow in the image shows fine pit (x40)

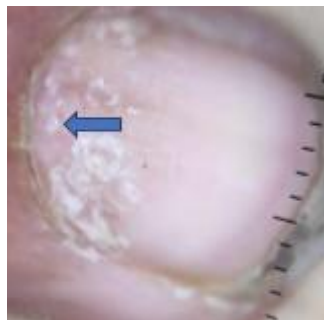

Figure 2: Arrow in the image shows coarse pit (x40)

Nail plate crumbling which was seen in 41.1% of the population both clinically and through dermoscope (FIGURE 3).

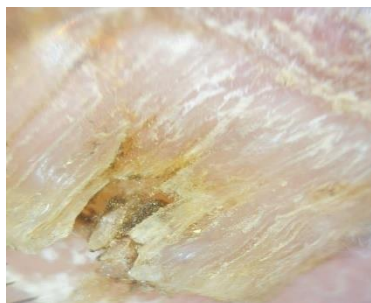


Figure 3: Arrow in the image shows nail plate crumbling (x40)

Leukonychia was seen in 26.6% of patients through dermoscope and clinically in 25.5% of the patients (FIGURE 4).

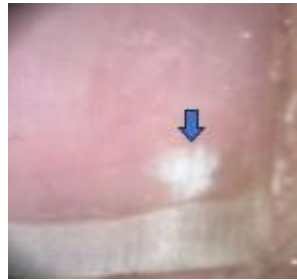

Figure 4: Arrow in the image shows leukonychia (x40)

The least common finding was Red lunula which was seen in 22.2% of the population both clinically and through dermoscope. The most common nail bed finding was Subungual hyperkeratosis seen in 63.3% of the patients both through dermoscope and clinical examination (FIGURE 5)

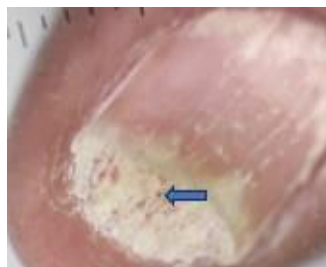

Figure 5: Image shows Subungual hyperkeratosis, arrow shows dilated hyponychial vessels (x40)

Onycholysis was seen in 55.5% of the population through dermoscope and 52.2% on clinical examination (FIGURE 6)

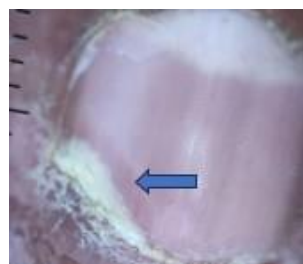


Figure 6: Arrow in the image shows onycholysis with erythematous halo (x40)

Splinter haemorrhage was seen in 28.9% of the population through dermoscope and 23.3% on clinical examination (FIGURE 7)

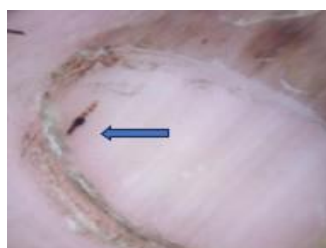


Figure 7: Image shows Fusiform splinter haemorrhage (x40)

The least common nail bed finding was Salmon patch (FIGURE 8)

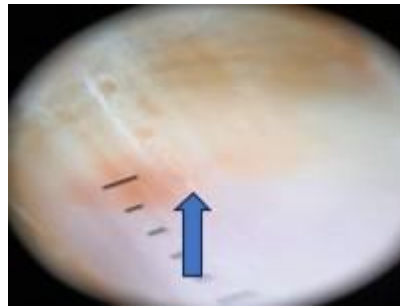


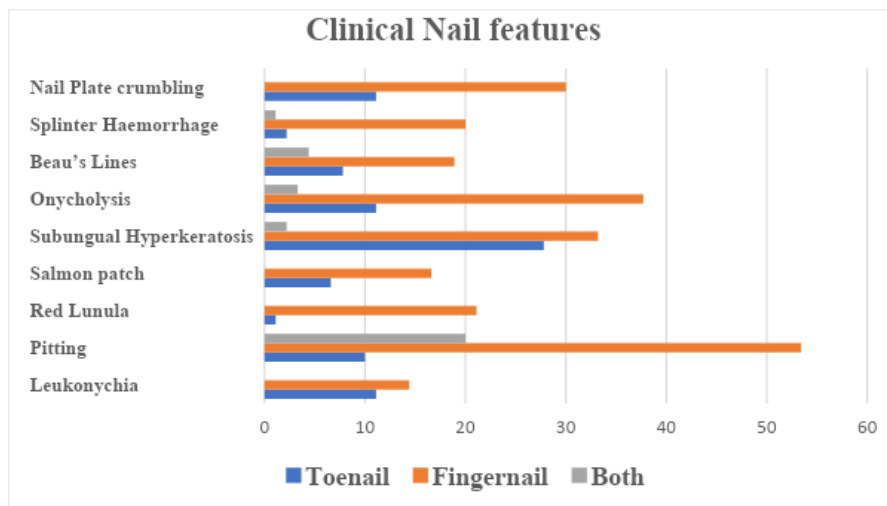
Figure 8: Arrow in Image shows salmon patch

It was present in 26.6% of the study population seen through dermoscope and clinically it was seen in 23.2% of the patients. Frequencies (%) of nail features summarised in TABLE 1, GRAPH 1 and 2.

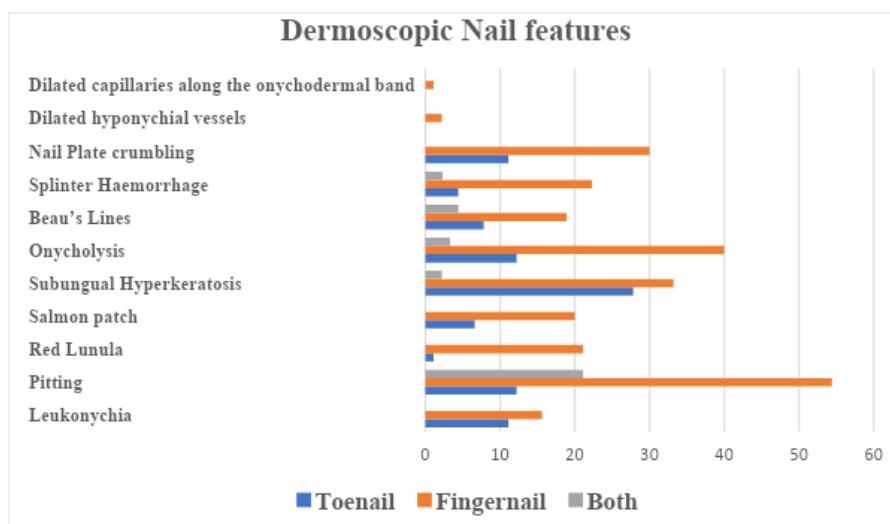
Table 1: Variables of Nail finding of Toenail and Fingernail expressed in percentage (%)

Nail Features	Nail Type	Clinical Finding (%)	Dermoscope Finding (%)
Leukonychia	Total	25.5	26.6
	Toenail	11.1	11.1
	Fingernail	14.4	15.6
	Both	0	0
Pitting	Total	83.4	87.7
	Toenail	10	12.2
	Fingernail	53.4	54.4
	Both	20	21.1
Red Lunula	Total	22.2	22.2
	Toenail	1.1	1.1
	Fingernail	21.1	21.1
	Both	0	0
Salmon patch	Total	23.2	26.6
	Toenail	6.6	6.6
	Fingernail	16.6	20
	Both	0	0
Subungual Hyperkeratosis	Total	63.3	63.3
	Toenail	27.9	27.9
	Fingernail	33.2	33.2
	Both	2.2	2.2
Onycholysis	Total	52.2	55.5
	Toenail	11.1	12.2
	Fingernail	37.7	40.0
	Both	3.3	3.3
Beau's Lines	Total	31.1	31.1
	Toenail	7.8	7.8
	Fingernail	18.9	18.9
	Both	4.4	4.4
	Total	23.3	28.9

Splinter Haemorrhage	Toenail Fingernail	2.2 20	4.4 22.3
	Both	1.1	2.2
Nail Plate crumbling	Total	41.1	41.1
	Toenail Fingernail	11.1 30	11.1 30
	Both	0	0
Dilated Hyponychial Vessel	Total	0	2.2
	Toenail Fingernail	0 0	0 2.2
	Both	0	0
Dilated Onychodermal Band	Total	0	1.1
	Toenail Fingernail	0 0	0 1.1
	Both	0	0



Graph 1: Graph shows frequency distribution of clinical nail features expressed in percentage (%).



Graph 2: Graph shows frequency distribution of dermoscopic nail features expressed in (%).

Other additional features like Beau’s line were seen in 31.1% both clinically and through dermoscope, dilated hyponychial blood vessel in 2.2% visible only in fingernail through dermoscope of the population (FIGURE 5) and dilated onychodermal band was seen in 1.1% visible only in fingernail through dermoscope (FIGURE 9). The Dermoscopic NAPSI value of the Toenail ranged from 0 to 23 (mean 9.62 ± 4.91). Clinical NAPSI of Toenail ranged from 0 to 21 (mean 8.48 ± 4.51). The Dermoscopic NAPSI value of Fingernail ranged from 3 to 28 (mean 16.09 ± 6.86). Clinical NAPSI of Fingernail ranged from 3 to 26 (mean 14.79 ± 6.64). Mean clinical and dermoscopic NAPSI scores are summarised in TABLE 2

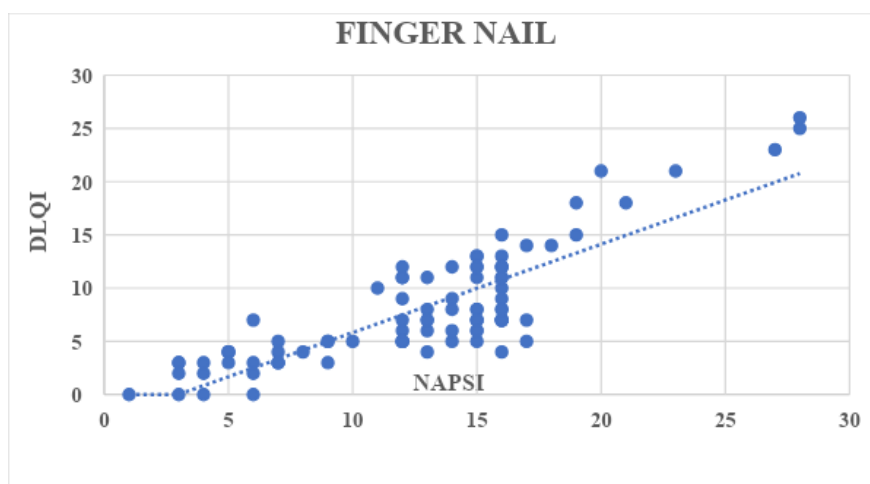
Table 2: Summary of clinical and dermoscope values of mean NAPSI score of Finger and toenail.

NAPSI	MEAN	STD.DEVIATION	MINIMUM	MAXIMUM
TOE NAIL NAPSI (Dermoscope)	9.62	4.914	0	23
FINGER NAIL NAPSI (Dermoscope)	16.09	6.867	3	28
TOE NAIL (Clinical)	8.48	4.518	0	21
FINGER NAIL (Clinical)	14.79	6.644	3	26

Wilcoxon signed-rank test was applied to compare the Dermoscopic NAPSI scores of the Fingernail and Toenail. There were 67 patients with fingernail NAPSI score higher than Toe nail and 22 patients had Toe nail NAPSI greater than Finger nail followed by only 1 patient having both NAPSI scores of Toe nail and Finger nail to be equal (Z is -5.729 based on negative rank test. The p-value was <0.001 which was statistically significant.

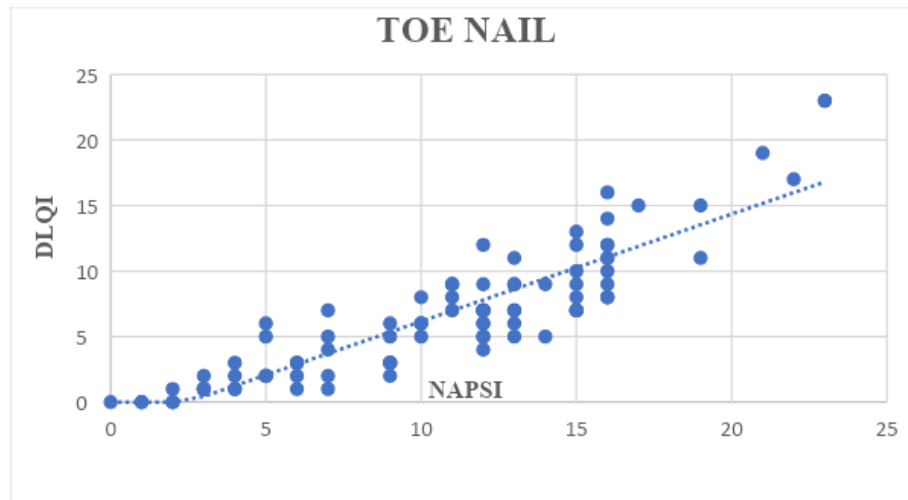
The mean DLQI for patients affected with fingernail psoriasis was 12.7 ± 5.5 . The mean DLQI for patients affected with Toenail psoriasis was 10.7 ± 5.4 . There was a positive correlation between DLQI and Dermoscopic fingernail NAPSI scores ($r=0.84$, P: value < 0.001) and was statistically significant (GRAPH 3).

Graph 3: Scatter plot showing correlation of dermoscopic NAPSI of fingernail with DLQI score.



There was a positive correlation between DLQI and Dermoscopic Toenail NAPS I scores ($r=0.89$ P: value < 0.001) and was statistically significant (GRAPH 4).

Graph 4: Scatter plot showing correlation of dermoscopic NAPS I of toenail with DLQI score.



DISCUSSION

The mean age in this study was mean 36.98 ± 9.22 years, which was similar to the study conducted by Daulatabad et al^[8] (36.3 years), lesser than those in studies conducted by Wanniang et al^[9] (45.02 years) but was higher than studies conducted by Polat et al^[1] (34.05 years) and Chauhan et al^[10] (28.9 years).

Male to female ratio in this study was 1.8:1, which shows male patients were more predominant than females. Similar features were seen in studies conducted by Chauhan et al^[10] (M: F = 2.66:1), Daulatabad et al^[8] (2.1:1), and Brazzelli et al^[11] (2.6:1).

In this study, the mean duration of Cutaneous Psoriasis was 4.22 ± 2.02 years, which was similar to the study done by Wanniang et al^[9] (4.9 years) whereas, the mean duration of nail psoriasis in their study was higher(4.3years) than the mean duration of Nail Psoriasis in this study was 2.79 ± 1.41 years. There was a higher mean duration of psoriasis (10.43 years) as well as the mean duration of nail involvement (5.86 years) in the study conducted by Polat et al.^[1]

Nail matrix involvement in psoriasis is associated with nail pitting, red spots in the lunula, leukonychia, and crumbling of the complete nail plate.^[12]

Pitting is caused by foci of parakeratotic cells beneath the apical matrix leaving behind depressions. More than 50 pits on all nails or more than 10 pits on a single nail is considered to be classical psoriasis.^[12]

The internal desquamation of keratinocytes that were unable to flake off due to the parakeratosis of the distal nail matrix causes leukonychia.^[13]

Red spots in the lunula represent active psoriasis lesions with dilatation of the capillaries and thinning of the suprapapillary plate. Red lunulae indicate dilatation of blood vessels of the nail matrix.^[14]

The crumbling of the plate is caused by Total matrix affection that results in

complete nail destruction. [12] The most common Nail matrix finding in this study was Pitting 87.7% through dermoscope and on clinical examination it was seen in 83.4% of the patients.

Similar findings were seen in a study conducted by Wanniang et al [9] where pitting was seen in 84% of the study population both through dermoscope and on clinical examination.

In a study conducted by Polat et al [1] Pitting was better appreciated clinically (92.5%) than through Dermoscope (77.5%).

The least common Nail matrix finding seen both clinically and through dermoscope in this study was Red Lunula which was seen in 22.2% of the study population both clinically and through dermoscope. Red spots were not seen in this study.

Red Lunula was the least common nail matrix seen in a study conducted by Polat et al [1] (5% red lunula both clinical and dermoscope). Wanniang et al [9] found that red lunula was seen only through dermoscope (5%) and was not seen clinically. Nail bed involvement causes subungual hyperkeratosis, onycholysis, salmon patch, and splinter haemorrhages. [15]

Focal parakeratosis of the nail bed causes the deposition of serum and cellular debris beneath the nail bed, which leads to the formation of oil spots or salmon patches. Onycholysis is formed by the extension of oil drop patches to the hyponychium. This deposition of cells that have not undergone desquamation can lead to subungual hyperkeratosis, which causes the nail plate to rise off the nail bed. [16]

Splinter hemorrhages have very thin, reddish-brown to black streaks that are a few millimeters long. They are comparable to Auspitz's phenomenon of the skin and are brought on by blood clots in these longitudinally distributed tiny vessels or bleeding from the dilated capillaries in the nail bed. [12]

In this study most common nail bed finding was subungual hyperkeratosis which was 63.3% in both clinical and through dermoscope (Toe nail 27.9%, Finger nail 33.2%, both 2.2%). A similar finding was seen by Chauhan et al [10], they found Subungual Hyperkeratosis was the most common nail bed finding on dermoscopy (52.8%-Finger nail and 85.1% toe nail) and clinical examination (Finger nail- 40.85% vs Toe nail 73.26%). However, subungual hyperkeratosis was seen more in Toe nails than finger nails which was contrary to this study as it was present more in finger nails than toe nails in this study population.

In a study conducted by Wanniang et al [9] subungual hyperkeratosis was seen in only 46% through dermoscope and 40% clinically, however onycholysis (54% both clinical and dermoscope) was the most common nail bed finding in the study.

Polat et al [1] study had onycholysis (Clinical-67.5%, Dermoscope- 77.5%) as the most common nail bed finding, Subungual hyperkeratosis was seen only in 35% clinically and 32.5% through dermoscope.

The least common nail bed finding in this study was a salmon patch. 26.6% of patients had Salmon patches seen through a dermoscope. Clinically, salmon patch was seen in 23.3% of the patients.

In a study conducted by Wanniang et al [9] 32% had salmon patches seen clinically and 44% were seen through dermoscope but the salmon patch was not the least

common nail bed finding in their study.

Polat et al^[1] found a salmon patch to be present in 42.5% of the patients clinically and 47.5% of the patients through dermoscope.

Yorulmaz and Artuz identified the pseudo-fiber sign as a new dermoscopic feature seen in nail psoriasis. They are red and black filamentous structures behind the distal free edge on the hyponychium, detached nail plate areas, and along the cuticle. These red and black fibers correspond to the arterial and venous ends of capillaries, respectively. In cuticular areas, they correspond to ruptured nail fold capillaries.^[17]

Pseudo fibre sign was not seen in this study. Dilated hyponychial capillaries were seen in 2.2% of the study population.

In a study conducted by Iorizzo et al, Hyponychium of psoriatic patients was studied and found that there was a correlation between the disease severity and capillary density.^[18] Yorulmaz and Artuz also observed that dilated, torturous hyponychial capillaries were associated with disease severity in their study.^[17]

Dilated capillaries along the onychodermal band surrounded by a prominent halo was observed by Yadav and Khopkar (19.5%).^[19] It was seen in only 1.1% of the study patients in this study.

In this study, the mean Dermoscopic NAPS I (fingernail) was higher than the Clinical NAPS I (fingernail) which was (16.09 ± 6.86 vs 14.79 ± 6.64).

This was similar to a study conducted by Wanniang et al^[9]. In their study the mean clinical NAPS I (Fingernail) score was 23.82 ± 16.12 , and was lesser than the mean dermoscopic NAPS I score (Fingernail) was 26.68 ± 16.07 .

In this study, the mean dermoscopic NAPS I score of the Fingernail was higher than that of the Toenail (16.09 ± 6.86 vs 9.62 ± 4.91).

The mean Dermoscopic NAPS I of fingernail higher than that of toenail was also seen in studies conducted by Chauhan et al^[10] (Fingernail -25.67 ± 15.57 vs Toenail - 6.36) and Rajasekar et al^[20] (Fingernail 23.81 ± 21.57 vs Toe nail 18.02 ± 12.21).

In this study, the mean DLQI for patients affected with fingernail psoriasis was higher than for Toenail (12.7 ± 5.5 vs 10.7 ± 5.3).

This could be probably due to the nature of occupation or regular wear and tear such as frequent exposure to water or liquid detergents which could potentially aggravate the underlying nail condition.

In a study conducted by Augustin et al^[21], mean DLQI was higher in psoriasis patients with nail involvement (with nail involvement 9.5 ± 7.1 vs without 7.6 ± 6.5) in females and males (with nail involvement 8.6 ± 7.1 vs without nail involvement 6.9 ± 6.3)

Kyriakou et al^[22] in their study found that the mean DLQI was 4.4 ± 2.9 in Psoriasis patients with nail involvement which was higher than those without nail involvement (mean \pm SD was 2.53 ± 1.18).

CONCLUSION

Pitting though can be observed clinically as well as dermoscopically, the size of pits, number where better examined using a dermoscope. Pits obscured by colorants like henna were also better recognized by dermoscope. Using a dermoscope makes it easy to identify a Splinter haemorrhage as well to differentiate various types like serpentine or fusiform, new or old lesion.

A linear erythematous border around the onycholytic area is crucial to extricate the other causes of onycholysis, which was appreciated better using a dermoscope. Dilated hyponychial vessels can be visualized better and most often only with a dermoscope.

From this study we conclude that each individual component of nail psoriasis was better enhanced using a dermoscope and the NAPSI score was precisely calculated than observed clinically.

Dermoscope being a non-invasive tool can help in meticulously identifying various features of nail psoriasis and to know the NAPSI score pre and post treatment. Dermoscopy also reduces the need of unnecessary biopsy and is boon to the treating physician and should be contemplated in daily practice for all cases of nail psoriasis.

DLQI scores were higher in patients with high NAPSI scores. This emphasizes that nail psoriasis can lead to significant psychological impact in the quality of life.

References

- 1) Polat A, Kapıcıoğlu Y. Dermoscopic findings of psoriatic nail and their relationship with disease severity. *Turkderm-Turk Arch Dermatol Venerology*. 2017; 51:119–23.
- 2) Lallas A, Zalaudek I, Argenziano G, Longo C, Moscarella E, Di Lernia V, et al. Dermoscopy in general dermatology. *Dermatol Clin*. 2013; 31:679–94.
- 3) de Jong EM, Seegers BA, Gulinck MK, Boezeman JB, van de Kerkhof PC. Psoriasis of the nails associated with disability in a large number of patients: results of a recent interview with 1,728 patients. *Dermatology*. 1996; 193(4):300-3.
- 4) Finlay AY, Khan GK. Dermatology Life Quality Index (DLQI)--a simple practical measure for routine clinical use. *Clin Exp Dermatol*. 1994; 19(3):210-6.
- 5) Grover C, Reddy BS, Uma Chaturvedi K. Diagnosis of nail psoriasis: importance of biopsy and histopathology. *Br J Dermatol*. 2005; 153(6):1153-8.
- 6) Hirata SH, Yamada S, Almeida FA, Enokihara MY, Rosa IP, Enokihara MM, Michalany NS. Dermoscopic examination of the nail bed and matrix. *Int J Dermatol*. 2006; 45(1):28-30.
- 7) Rich P, Scher RK. Nail psoriasis severity index: A useful tool for evaluation of nail psoriasis. *J Am Acad Dermatol*. 2003; 49:206–12.
- 8) Daulatabad D, Grover C, Kashyap B, Dhawan AK, Singal A, Kaur IR. Clinical and serological characteristics of nail psoriasis in Indian patients: A cross-sectional study. *Indian J Dermatol Venereol Leprol*. 2017; 83(6):650-655.
- 9) Wanniang N, Navya A, Pai V, Ghodge R. Comparative Study of Clinical and Dermoscopic Features in Nail Psoriasis. *Indian Dermatol Online J*. 2020; 11(1):35-40.
- 10) Chauhan A, Singal A, Grover C, Sharma S. Dermoscopic Features of Nail Psoriasis: An Observational, Analytical Study. *Skin Appendage Disord*. 2020; 6(4):207-215.
- 11) Brazzelli V, Carugno A, Alborghetti A, Grasso V, Cananzi R, Fornara L, De Silvestri A, Borroni G. Prevalence, severity and clinical features of psoriasis in fingernails and toenails in adult patients: Italian experience. *J Eur Acad Dermatol Venereol*. 2012; 26(11):1354-9.

- 12) Haneke E. Nail psoriasis: clinical features, pathogenesis, differential diagnoses, and management. *Psoriasis (Auckl)*. 2017; 7:51-63.
- 13) Tosti A, Piraccini BM: Nail disorders. In: *Dermatology* (Bolognia JL, Jorizzo JL, Rapini RP eds.), 2nd ed. St. Louis, MO: Mosby Elsevier; 2008:1061-77.
- 14) Peña-Romero A, Toussaint-Caire S, Domínguez-Cherit J. Mottled lunulae in nail psoriasis: report of three cases. *Skin Appendage Disord*. 2016; 2(1–2):70–71.
- 15) Rigopoulos D, Baran R, Chiheb S, Daniel CR 3rd, Di Chiacchio N, Gregoriou S et al. Recommendations for the definition, evaluation, and treatment of nail psoriasis in adult patients with no or mild skin psoriasis: A dermatologist and nail expert group consensus. *J Am Acad Dermatol*. 2019; 81(1):228-240.
- 16) Zhou, Xu-Yue; Zhang, Jia-An; Chen, Kun. Nail Psoriasis: Treatment Options and Management Strategies in Special Patient Populations. *Int J Dermatol Venereol*. 2022; 5(1):32-9.
- 17) Yorulmaz A, Artuz F. A study of dermoscopic features of nail psoriasis. *Postepy Dermatol Alergol*. 2017; 34(1):28-35.
- 18) Iorizzo M, Dahdah M, Vicenzi C, Tosti A: Videodermoscopy of the hyponychium in nail bed psoriasis. *J Am Acad Dermatol* 2008; 58:714-5.
- 19) Yadav TA, Khopkar US. Dermoscopy to Detect Signs of Subclinical Nail Involvement in Chronic Plaque Psoriasis: A Study of 68 Patients. *Indian J Dermatol*. 2015; 60(3):272-5.
- 20) Rajshekhar S, Vellaisamy SG, Manickam N. Prevalence of nail changes in patients and correlation of NAPSI (Nail Psoriasis Severity Index) with BSA (Body Surface Area). *IP Indian J Clin Exp Dermatol* 2018; 4;116-22.
- 21) Augustin M, Reich K, Blome C, Schäfer I, Laass A, Radtke MA. Nail psoriasis in Germany: epidemiology and burden of disease. *Br J Dermatol*. 2010; 163(3):580-5.
- 22) Kyriakou A, Patsatsi A, Sotiriadis D. Quality of life and severity of skin and nail involvement in patients with plaque psoriasis. *Eur J Dermatol*. 2014; 24(5):623-5.